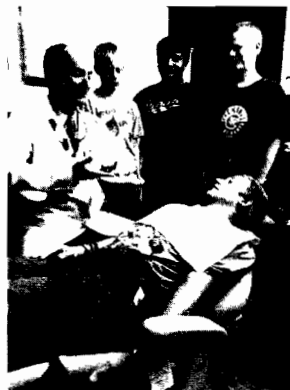

DENTISTRY



BOY SCOUTS OF AMERICA
IRVING, TEXAS

Requirements

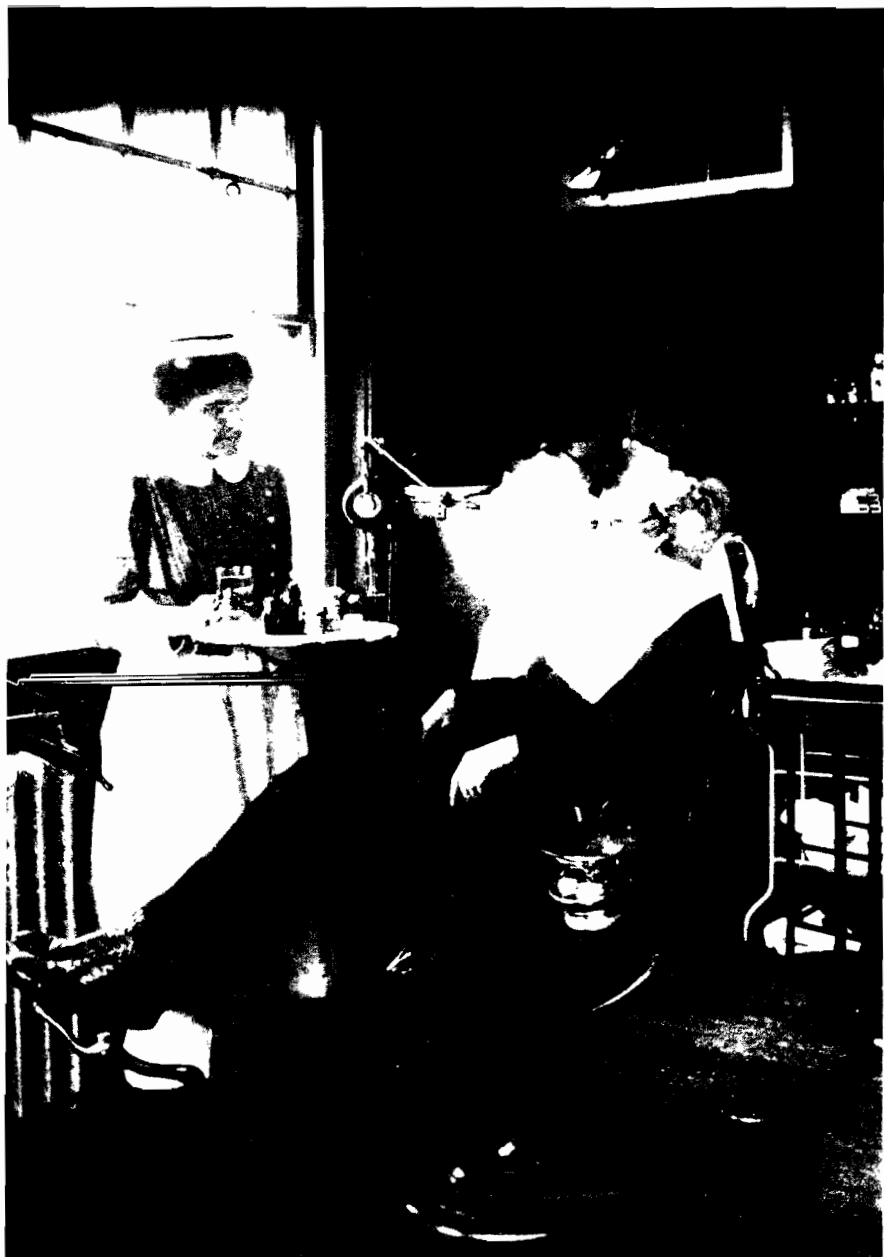

1. Using X-ray (radiographic) films and with your counselor's guidance, study the tooth structure and look for decay. Then do the following:
 - a. Using the radiographs as a guide, draw a lower molar. Label its parts and surfaces. Show surrounding structures such as bone and gum tissues.
 - b. Show on your drawing where the nerves and blood vessels enter the tooth.
 - c. Show on your drawing where bacterial plaque is most likely to be found.
2. Do the following:
 - a. Tell or write about what causes dental decay and gum disease. Tell how each of the following contributes to dental decay and gum disease: bacterial plaque, sugars, and acid.
 - b. Tell the possible causes for traumatic tooth loss, describe the types of mouth guards used to help prevent tooth trauma, and list the athletic activities during which a person should wear a mouth guard.
 - c. Explain the first-aid procedure for saving a tooth that has been knocked out.
3. Arrange for a visit with a dentist. Before you go, ask whether your visit can include a dental examination and a plaque-control demonstration. Afterward, ask questions about things you want to know. Then tell your counselor what the dentist does during a checkup examination.



4. Do TWO of the following:
 - a. Name at least five instruments and five pieces of equipment a dentist uses.
 - b. With the help of a dentist, prepare a dental stone cast using a vibrator, a mixing bowl, a water measure, a plastic measure, model stone, and a spatula.
 - c. Keep a record of everything you eat for three days. Circle those items that may provide the sugars that bacterial plaque needs to make acid. List snacks that you should avoid to help maintain the best oral health.
5. Discuss with your merit badge counselor the following:
 - a. How fluorides help prevent tooth decay and the ways fluorides can be provided to the teeth.
 - b. How the mouth is related to the rest of the body. Topics might include chewing, saliva, enzymes, nutrition, and speech.
6. Do TWO of the following:
 - a. Make a model tooth out of soap, clay, papier-mâché, or wax. Using a string and a large hand brush, show your troop or a school class proper toothbrushing and flossing procedures.
 - b. Make a poster on the prevention of dental disease. Show the importance of good oral health.
 - c. Collect at least five advertisements for different toothpastes. List the claims that each one makes. Tell about the accuracy of the advertisements.
 - d. Write a feature story for your school newspaper on the proper care of teeth and gums.
 - e. Make drawings and write about the progress of dental decay. Describe the types of dental filling and treatments a dentist can use to repair dental decay problems.
7. Find out about three career opportunities in dentistry. Pick one and find out the education, training, and experience required for this profession. Discuss this with your counselor, and explain why this profession might interest you.





Contents

The History of Dentistry	7
The Tooth	10
Keeping Your Teeth for a Lifetime	21
At the Dentist's Office	37
Careers in Dentistry	55
Dentistry Resources	62



The History of Dentistry

Since the earliest people got their first teeth, humans have suffered mightily from gum disease and tooth decay. Treating these dental problems often caused more pain than the disease itself, so it is no wonder that people feared—and still fear—the tooth-puller.

In many ancient cultures, the tooth represented vitality and immortality. When someone had a toothache, spiritual leaders would treat it with amulets, prayers, and incantations. Mystery and superstition surrounded the tooth's power to produce pain. Demons were blamed. And tooth worms. Many people believed that worms bored holes into the teeth and caused pain by thrashing about. Healers tried to smoke the worms out of the cavities or kill them with concoctions of urine and spider juice. This belief persisted into the Middle Ages.

Hippocrates (from ancient Greece, known as the Father of Medicine) suggested that people were prone to toothaches if their bodily fluids, or *humors*, were out of balance. He recommended treating infected teeth with cauterization and astringents, and even bloodletting. This idea of opening a vein to let blood out was popular even in the 1900s.

At one time medicine and dentistry were not separate professions. As the practice of bloodletting caught on, physicians decided it was “beneath them” to perform the procedure, thinking that it was the work of butchers. Priests were forbidden to shed blood, so barber-surgeons took to cutting hair and pulling teeth.

For thousands of years, gum disease caused by excessive wear from chewing coarse foods accounted for most tooth loss. But as civilizations developed and refined sugar found its way into the diet, tooth decay claimed more teeth. Sugar was expensive, so the wealthy were more likely than poor people to suffer from *caries*, or tooth decay.

During the Renaissance, when the arts and sciences flourished, lead and gold fillings were used for the first time to stop tooth decay. In 1683, the Dutch naturalist Anton van Leeuwenhoek looked into his microscope and discovered *animalcules* (bacteria) in his tooth scrapings (*plaque*).

In 1728, Pierre Fauchard, who is regarded as the father of modern scientific dentistry, published his book *The Surgeon-Dentist, or Treatise of the Teeth*. In it he put forth several ideas that are still current: the importance of keeping the teeth clean because oral health affects the whole body; the need for specialized dental education; the necessity of scaling teeth and cleaning the root surfaces to prevent gum or *periodontal* disease; the need to align teeth in the jaw; and instructions for using ivory in dentures, connecting them with springs, and coloring the artificial teeth.

Dentistry, as a distinct field of medicine, developed in the 1800s. Baltimore College of Dental Surgery, the first dental college in the world, was founded in 1840. At the same time, Horace Wells discovered that he could perform painless tooth extractions by giving nitrous oxide gas—laughing gas—to his patients. Then William Morton successfully used ether as a general anesthetic. In 1858, local anesthetics were given by injection of a drug made from cocaine.

In 1890, Willoughby D. Miller, an American dentist, discovered how plaque forms and can lead to the destruction of teeth. Other dentists began to teach preventive measures for getting rid of plaque and avoiding tooth decay and gum disease. X-ray photos of the teeth were taken for the first time in 1896.



Dental treatment has evolved rapidly in the past century. Adding fluoride to the public water supply has dramatically reduced the incidence of tooth decay. Dental drills and ultrasonic cleaning tools help make a visit to the dentist's office quick and more pleasant. We can be glad that the days of the tooth worm are behind us.



The development of things like newer and stronger bonding agents, technologically advanced orthodontic and facial surgical procedures, and safer anesthetics has made today's dentistry as sophisticated, accurate, and safe as any other modern field of medicine.



The Tooth

Your pearly whites do a lot more than just peek out from under that winning smile. Teeth have all sorts of duties, so the next time the dentist asks you to open wide, remember that healthy teeth will help you eat, speak, and look great!

Eating. The main function of teeth is to break food into small pieces that you can swallow safely and digest. The different shapes and structures of teeth allow for the different functions of biting, tearing, and grinding.

Speech. Although every normal child is born with a voice, he or she must learn to speak. The parts of the body designated for breathing, chewing, and swallowing work together to create speech. The teeth help to form words.

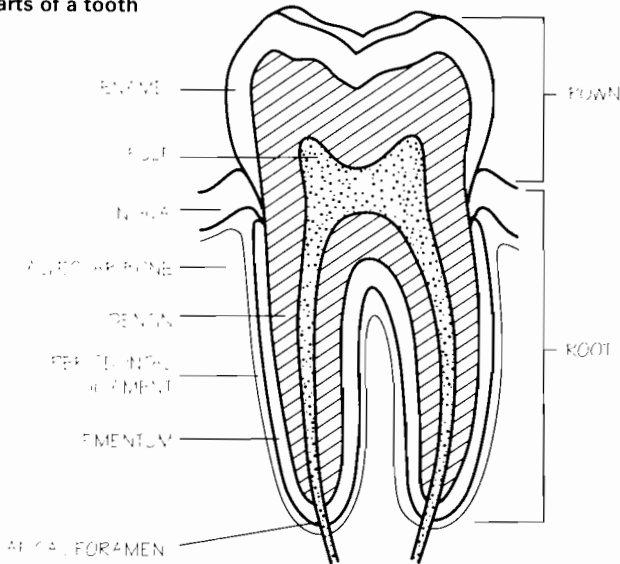
Appearance. Teeth help to form the shape of the face. The canines, or cuspids, at the corners of the mouth give the smile a pleasant symmetry. But missing teeth may turn a smile into an embarrassed tight-lipped expression or make the cheeks look hollow.

Humans are omnivores. We eat everything—animal and plant materials—so we need teeth that will grind a steak, crush a pinto bean, and slice off a piece of celery.

The Structure of the Tooth

The two basic parts of a tooth are the *crown* and the *root*. The tooth is a living structure, made up of four dental tissues: *enamel*, *dentin*, *cementum*, and *pulp*.

Parts of a tooth



The bones that hold the teeth consist of the upper bones of the mouth, called the maxilla, and the two lower bones of the mouth, called the mandible.

The Crown

The crown is the part of the tooth visible above the gum. An outer layer of enamel protects it from wear and decay. The hard surface on the top of the crown is for biting and chewing.

The Root


The root is the part of the tooth that is below the gum and holds the tooth in the bone. It makes up almost two-thirds of the total length of the tooth. In a healthy mouth, the root should not be visible. It is firmly embedded in a socket in the jaw and protected on its outer surface by a thin layer of hard tissue called *cementum*. Depending on its function, a tooth may have one, two, or (though uncommon) three roots.

Enamel

Composed of calcium and phosphate crystals, enamel is the hardest substance in the human body. It protects the dentin and pulp from the impact of grinding and chewing, as well as from corrosive acids and enzymes in the mouth. Because of its unique structure, enamel can withstand drastic temperature changes. For example, your tooth enamel won't crack if you eat a bowl of ice cream and then drink a mug of hot apple cider.

Even though enamel is hard, it is still vulnerable. When a tooth *erupts* (comes through the gum), the cells that make enamel die. Without living cells, enamel has no way to repair itself. So any defects that occurred when the enamel formed, or any damage sustained from decay or wear, will always remain.

Tooth enamel reacts with various minerals in the mouth and gets harder over time, which might be why children often have tooth decay (or caries), but people older than 20 rarely do.



A tooth is not really white. Enamel has a gray or bluish tint. It is semitransparent and reveals the color of the dentin underneath.

Dentin

Dentin is a bonelike tissue that makes up the main portion of the tooth. At the crown, dentin is covered with enamel; at the root, with cementum. It is a highly porous, slightly yellow substance that, when stained by foods, drinks, tobacco, or antibiotics, can turn orange, brown, or black. Dentin surrounds the pulp, except at the end of the root (the *apical foramen*) where the blood vessels and nerves enter the pulp cavity.

Cementum

Cementum is a thin, hard tissue that covers and protects the outer surface of the root. It is softer than enamel and similar to bone but without the blood vessels and nerves. It is attached to the fibers of the periodontal ligament, helping connect the root to the bone.

Pulp

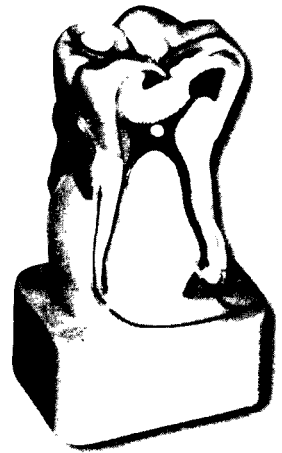
Pulp is the soft tissue that occupies a space inside the tooth called the pulp cavity or chamber. The pulp extends down the roots of the tooth in the pulp canals, or root canals, to the apical foramen where the pulp tissue leaves the tooth and enters the bone. It contains sensory nerves, blood vessels, odontoblasts (a kind of cell), and fibrous connective tissue.

The blood cells and lymph vessels connect the tooth with the rest of the body; they supply nutrients for the dentin but can also spread disease and infection throughout the body. Odontoblasts are cells that make up the outer lining of the pulp and extend through narrow channels, or tubules, into the dentin. These cells continually form new dentin. The dentin tends to grow inward, making the pulp chamber and root canals smaller. Over time, the tooth becomes insensitive. However, if the pulp is damaged or dies, then the dentin will no longer be maintained, and the tooth will die.

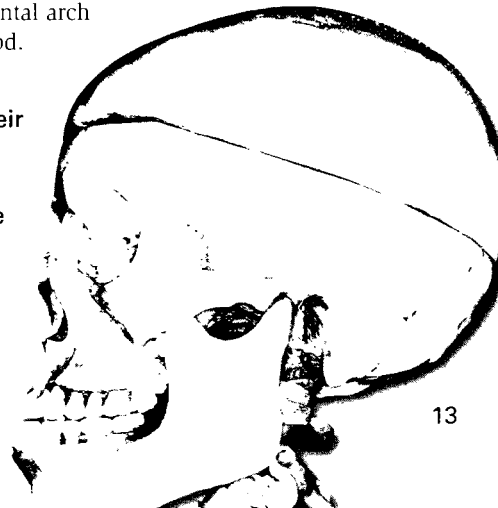
Different Teeth for Different Tasks

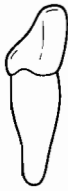The shape of the tooth determines its function. The six front teeth in the upper and lower jaws have single, sharp edges—like knives. The 10 back teeth in each dental arch have large blunt surfaces for grinding food.

Humans chew mainly by moving their lower jaw up and down, with only a slight side-to-side motion. The front teeth slide across each other like the blades of scissors, and the back teeth meet with force to crush and compress the food like a compactor.

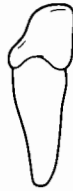

A dead tooth may or may not need to be extracted. If the tooth's pulp is damaged, you may need a root canal to prevent the tooth from dying.

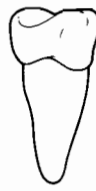



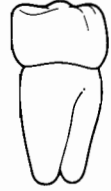Incisor



Canine, or cuspid



Bicuspid



Molar

Incisors

The four flat front teeth in both the upper and lower dental arches (the central and lateral incisors) have spade-shaped edges for cutting and slicing. Incisors typically have a single root.

The canines, or cuspids, are also known as “eyeteeth.” Folk wisdom held that the eyeteeth were connected to the eyes, and that pulling an eyetooth could make the patient blind.

Canines, or Cuspids

These four “doglike” teeth next to the lateral incisors each have a single *cuspid*, or point on the surface, for holding and tearing food.

The root of the canine is extra long and large to secure the tooth in the bone so it won’t come loose from the tearing movements. The surface of the tooth is smooth and the cusp is rounded, so the canine tends to be self-cleaning. Because the tooth is resistant to decay and is firmly anchored in the jawbone, the canine is often the last tooth lost to age.

Bicuspids


Often called premolars, these first and second bicuspids share characteristics with molars and canines. They each have a large chewing surface, like the molar, and cusps (in this case, two), like the canine. These teeth crush *and* tear food. Bicuspids have one, two, or sometimes three roots.

Molars

The third molars, also called the *wisdom teeth*, most often appear during the late teens or early 20s.

The two or three teeth farthest back in the mouth are the molars (first, second, and third). These are the largest teeth, with broad surfaces and three to five cusps for grinding. The curving roots of the molars anchor the teeth deeply in the jawbone to withstand the tremendous chewing pressures exerted. The lower molars have two roots, and the upper ones almost always have three.

Meat-eating animals such as tigers have oversized cuspids for killing and eating their prey.





Support for the Tooth

The supportive tissues of the tooth are called the *peri-odontium*, which includes the *periodontal ligament*, the *alveolar bone*, and the *gingiva*, or gums. The cementum, periodontal ligament, and alveolar bone connect the teeth to the jaws. When one of these is damaged or missing, the tooth will loosen and eventually fall out. The supportive tissues actually get stronger from vigorous use. However, if a part of the mouth is not used because of missing teeth, *malocclusion* (a “bad bite”), or pain from advanced caries, then the supporting structures will weaken and cause much damage.

Periodontal Ligament. This strong, fiberlike tissue anchors the root to the bone and cushions the surrounding bone against the shock of chewing and biting. When extracting a tooth, the dentist cuts the periodontal ligament that connects the tooth to the bone.

Alveolar Bone. The bony part of the upper and lower jaws that surrounds and supports the roots of the teeth and the gums is called the alveolar bone. *Alveolar* means “hollow.” The alveolar bone has hollow places, or *sockets*, that house the roots of the teeth.

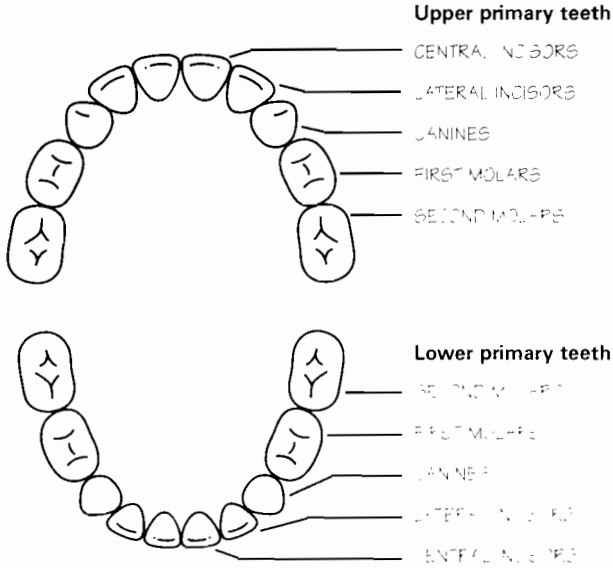
Gingiva. This thick pink tissue—known as the gums—covers the necks of the teeth and all of the alveolar parts of the jaws. It fits tightly, except for gaps between the tooth and gum, called *gingival crevices*, where food particles and bacteria can collect. If teeth are not cleaned carefully and frequently, then *calculus*, a material made when plaque hardens, will form and periodontal (gum) disease will set in.



Healthy gums, *left*, fit tightly around the whole root and part of the enamel. Unhealthy gums, *above*, leave gaps, increasing the potential for disease and tooth decay.

Development and Eruption of Teeth

Under normal circumstances, you will develop two sets of teeth in your lifetime: the primary set and the permanent set.



Primary Teeth

The first set of teeth—called primary, baby, milk, or deciduous—is temporary but affects the future of your mouth in important ways. These teeth help to form facial contours and help you develop speech and the ability to chew. They also maintain space so that the permanent teeth can erupt in the correct formation.

Proper care of the primary teeth is critical. Decay and infections can spread to the permanent teeth even before they have emerged. Premature loss of baby teeth to decay or accidents may cause permanent teeth to erupt in the wrong positions, requiring orthodontic treatment (such as braces). If a tooth comes out before it is supposed to, the dentist will decide whether to replace it. Sometimes the jaw is growing quickly, spaces are naturally occurring, and the permanent tooth has room to erupt. However, the dentist may fit a metal or plastic device into the gap to help maintain that space until the permanent tooth is ready to come in.



Baby teeth form as tiny buds while the child is still in the mother's womb. At birth, all primary teeth and the permanent first molars are present but still below the gums. When the baby is around 6 months of age, some of the primary teeth are ready to slowly slide through the gums. At the time an incisor erupts, the root is only two-thirds formed. It may take four years after the tooth appears for the apical foramen, periodontal ligament, cementum, and alveolar bone to fully develop.

-Mamelons



The small bumps on the biting surface of the tooth are called *mamelons*. They will wear down in a few years as the teeth contact the teeth of the opposing jaw. If they don't, then the dentist probably will check for malocclusion, a problem with the way the teeth meet when the jaws close.

Healthy primary teeth should be a milky white color. Tooth color other than white indicates a malformation of the enamel and a great risk for tooth decay.

The set of primary teeth includes 20 teeth, 10 each in the upper and lower jaws. Each jaw, or *dental arch*, contains two central incisors, two lateral incisors, two canines or cuspids, two first molars, and two second molars. These erupt in sequence, starting with the lower central incisors and then the upper central incisors. The alternating eruption pattern of matching teeth in opposing jaws ensures that the child can bite and chew, and therefore digest, food properly.

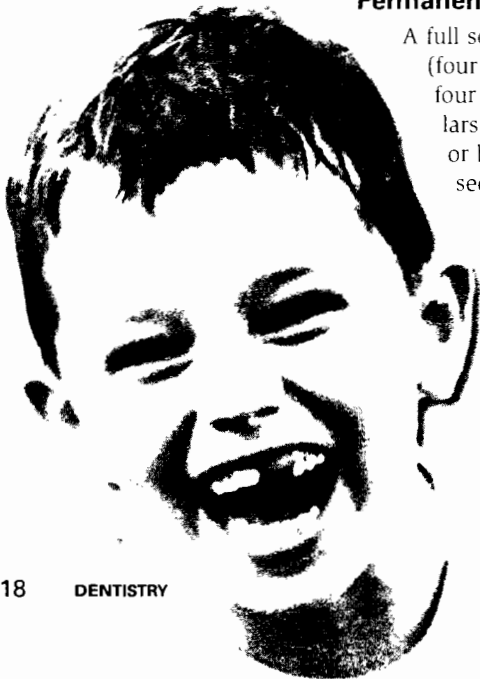The sequence of eruption is more important than when the teeth erupt. Boys' teeth tend to erupt later than girls' teeth. This may be an advantage because teeth that remain under the gum longer have a higher resistance to dental caries because of the extra time the tooth has to absorb the chemical compound fluoride. Most 3-year-olds have a complete set of primary teeth with fully developed roots.

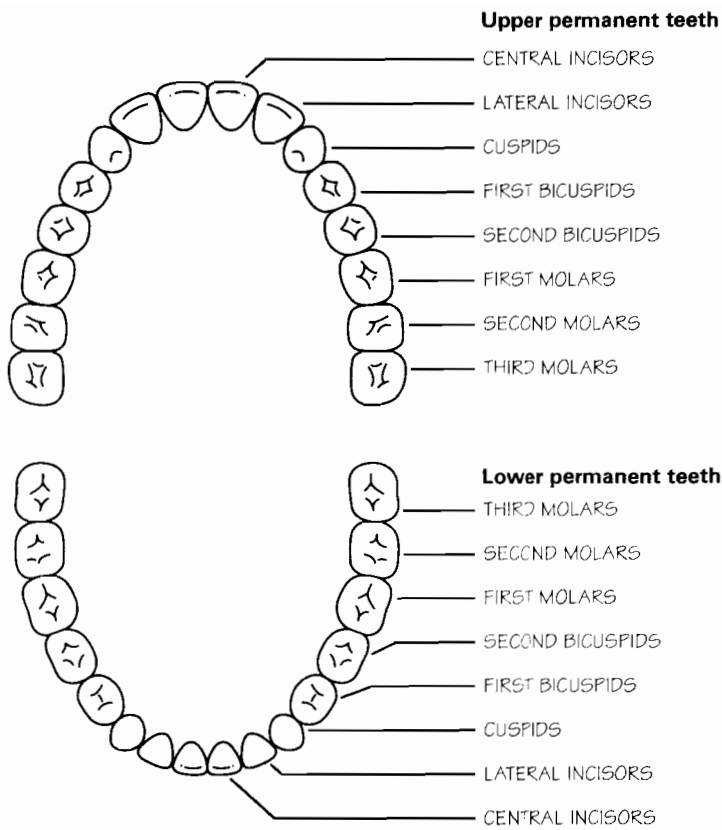
Around the age of 4, the child's jaws grow dramatically, creating gaps between the teeth. Then, at 6, the permanent first molars erupt. The roots of the primary teeth begin to dissolve (or resorb), the crowns lose support, and the teeth fall out (*exfoliate*).

Permanent Teeth

A full set of permanent teeth has 32 teeth (four central incisors, four lateral incisors, four canines or cuspids, four first premolars or bicuspid, four second premolars or bicuspid, four first molars, four second molars, and four third molars, or wisdom teeth). By the age of 13, most people have 28 permanent teeth. The third molars erupt (if at all) by the early 20s. The permanent teeth are yellowish in color, much larger than primary teeth, and closely spaced.

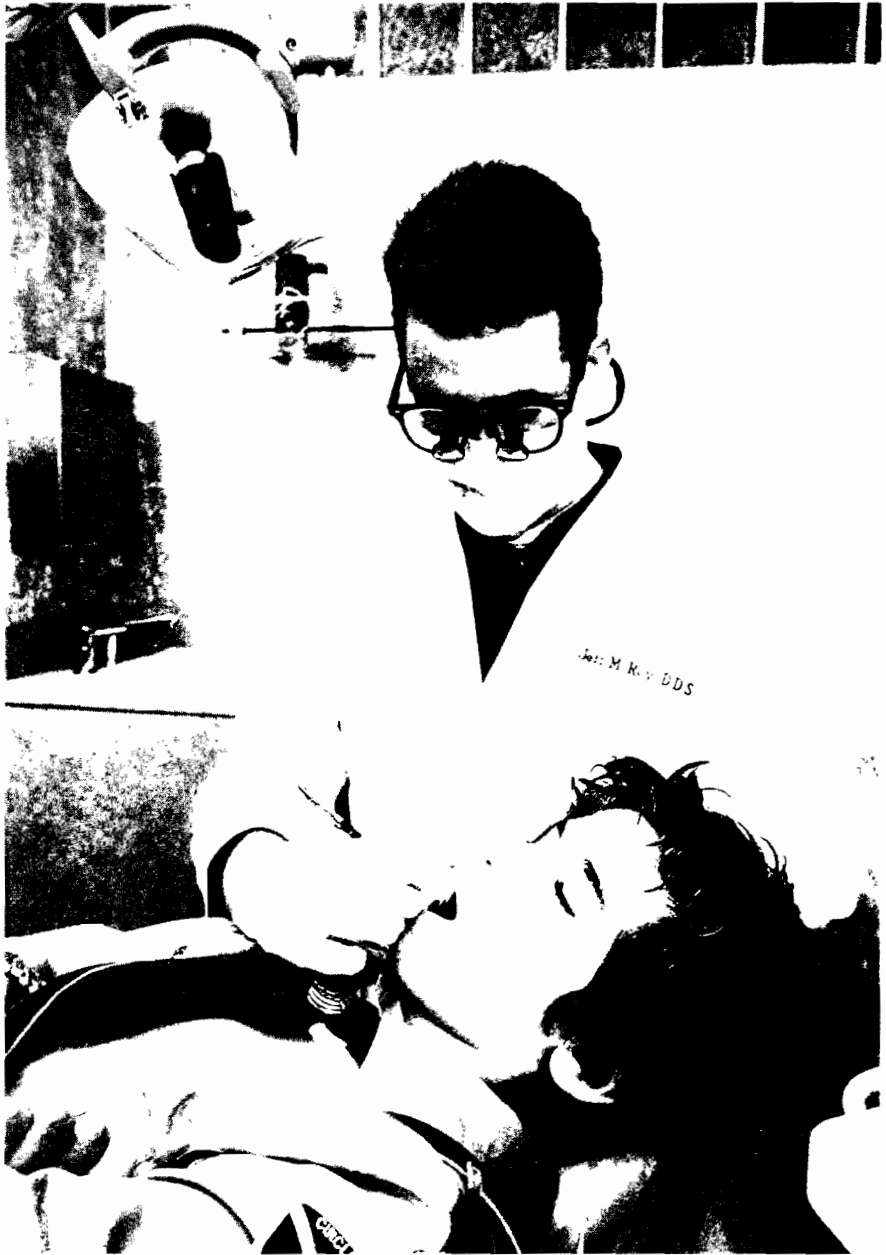The first molar (6-year-old molar) is the first permanent tooth to erupt and is the key to





proper placement of the permanent teeth. If it emerges in the correct position, with healthy primary teeth next to it, it serves as a guide for the rest of the permanent teeth. But if the primary tooth next to the first molar is missing, the molar will tip or drift out of position and misdirect the eruption of the other teeth.





Keeping Your Teeth for a Lifetime

Once your permanent teeth replace your primary teeth, you are set for the rest of your life. If you take care of these teeth, you can avoid having to buy a third set—dentures.

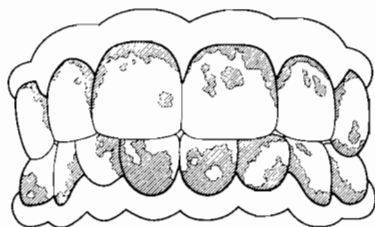
Enemies of Your Teeth and Gums

Tooth decay, or dental caries, is a destructive infectious disease caused by specific bacteria that feed on sugars in food and produce enamel-attacking acids. If left untreated, decay will work its way through the enamel, dentin, and pulp and eventually to the alveolar bone. In the worst case, the infection could spread through the bloodstream to other parts of the body, causing specific reactions that could result in death.

Plaque

Tooth decay generally begins with the formation of plaque, which contains a sticky substance called *dextran*. Bacteria digest sugars, producing dextran and acids. Plaque sticks to teeth and dental restorations (crowns, bridges, fillings, dentures, and implants) and holds those acids in close contact with the tooth surface.

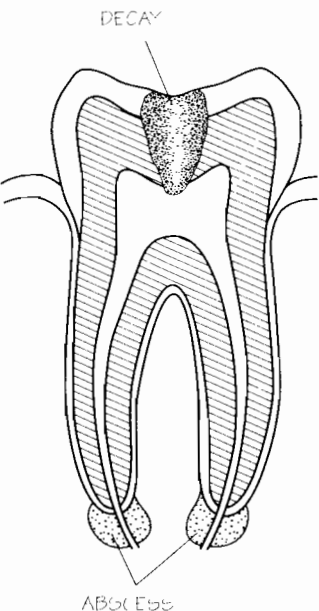
Plaque accumulates in the pits and fissures of the molars and bicuspid, between teeth, and in crevices below the gum line. If it is not removed quickly and the acids are left undisturbed, the acids will react chemically with the minerals in enamel and dissolve them. The cycle of plaque formation and the process of tooth decay continue as long as colonies of bacteria are permitted to cling to the plaque on the teeth and feed on the constant supply of sugar that is introduced throughout the day, every day.



Plaque typically accumulates in hard-to-reach places—the pits and fissures of teeth, between teeth, and in crevices below the gum line.

Calculus

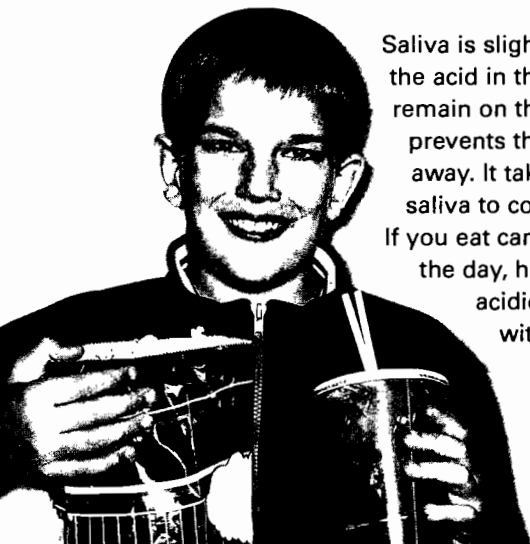
You can remove plaque easily by brushing and flossing diligently. But if you ignore plaque, it will eventually absorb calcium salts from saliva and harden into calculus, or *tartar*. Because calculus is rough and impossible to scrape off without special dental tools, it attracts more bacteria, which irritate and inflame the gums.



Acids

Strong acids in the mouth can dissolve enamel, causing holes—or *cavities*—in the teeth. As the cavity gets bigger, the acids can reach the softer dentin, which is more susceptible to caries. If the cavity is not treated, bacteria can swarm through the dentin to the pulp and attack the nerves and blood vessels. The pulp gets infected but cannot swell inside the tooth, so the infection spreads through the root canals into the tooth socket, causing an abscess.

Besides eating sugary foods, which bacteria use to produce acids, you may do other things that cause strong acids to attack the teeth and irritate the gums. Sucking on a lemon, putting an aspirin directly on a mouth sore, drinking carbonated beverages that contain acids as well as sugar, and bingeing and purging (an eating disorder called *bulimia*) all expose the mouth to corrosive stomach acids. Additionally, a condition known as gastroesophageal reflux disease, or GERD, can have a devastating effect on the enamel in teeth.




Saliva is slightly alkaline and can neutralize the acid in the mouth. If plaque is allowed to remain on the teeth, it locks in the acids and prevents the saliva from washing them away. It takes 20 to 40 minutes for the saliva to completely neutralize the acids. If you eat candy or drink sodas throughout the day, however, your mouth will stay acidic and decay will continue without a break.

Sugars

Sugar is the main staple in the diet of plaque-forming bacteria. If you reduce the amount of sugar you eat, bacteria do not have as much fuel to produce tooth-destroying acid. However, the more sugar you eat, the more acids the bacteria produce to attack the teeth.

Sweets are particularly harmful because they stay in or stick to the mouth for a long time: hard candy, cough drops, breath mints, non-sugarless chewing gum, caramels, pastries, and dried fruit. If starch sticks to the teeth, an enzyme in saliva called *amylase* can convert the starch to sugar, and then the acid-producing cycle starts again.



Tobacco

Smoking and chewing (smokeless) tobacco do not cause tooth decay but will, at the very least, stain your teeth and foul your breath. Tobacco irritates the soft tissues of the mouth—gums, tongue, *palate* (the roof of the mouth), and lining of the cheeks. It can cause sores, a white plaque on the roof of the mouth, or even oral cancer. In fact, the use of either smoking or chewing tobacco is considered to be the leading cause of oral cancer. Smokers are four to 15 times more likely to get oral cancer than nonsmokers.



Tobacco does more than just stain teeth. Users are more likely than nonusers to suffer from excessive tartar buildup and periodontal disease, to get oral cancer, and—as an added bonus—to have bad breath.

Tobacco users are more likely than nonusers to suffer from periodontal disease. Smoking depletes vitamin C, which healthy gums need. Nicotine constricts the blood vessels, limiting the supply of blood and oxygen to the tissues. These factors, along with excessive tartar buildup (particularly for pipe smokers), increase the risk of getting gum disease. In fact, tobacco may interfere with the treatment of gum disease and make it ineffective.



Genetics


Many factors affect the development of teeth and of oral and facial structures. During pregnancy, the mother may be exposed to chemical or environmental hazards. She may run a high fever for a long time, take certain medications or substances (such as alcohol or drugs), or have severe nutritional deficiencies. All of these influences can cause defects in the enamel and dentin of the baby's teeth, especially if they happen while the teeth, jaws, and face are forming.

Heredity plays a major part in the health of the teeth and supporting structures. "Good" or "bad" teeth can run in the family. Genetics determines how white teeth are, how quickly and how much the teeth will discolor, whether gums are predisposed to chronic swelling, and whether a person might develop an autoimmune disease that dries out the saliva and keeps it from neutralizing acids.

The range of possible genetic defects includes missing a complete set of permanent teeth; developing too many teeth or teeth that are unusually small or large; teeth that are fused together or share one root canal; a cleft lip and/or palate; and upper and lower jaws that don't match in size or meet properly.

Preventing Tooth Decay and Gum Disease

Although you can't control what kind of teeth you inherit, you can control how well you try to prevent tooth decay and gum disease. You accomplish this by developing good habits of oral hygiene and making good choices about eating.



How to Brush

The key to preventing caries and periodontal disease is controlling plaque. Whether you use a manual or electric toothbrush, or toothpaste or tooth gel, is not as important as whether you brush your teeth regularly, thoroughly, and correctly.

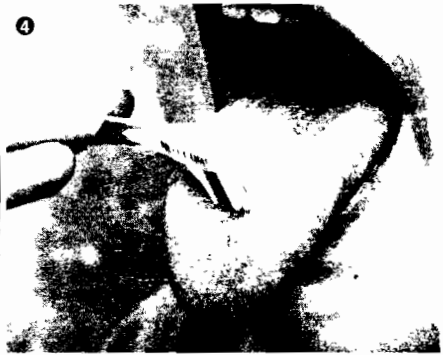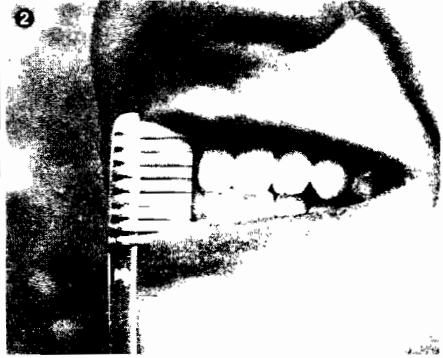
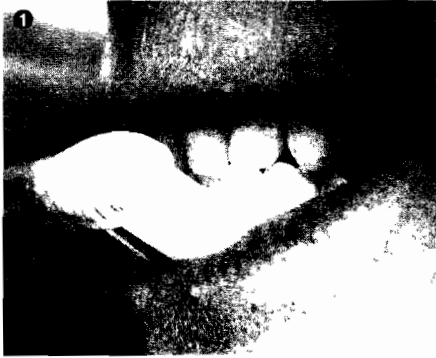The American Dental Association (ADA) suggests selecting a toothbrush that is small enough to reach every face of the teeth, with soft, round-ended bristles, a flat brushing surface, and a straight handle. A dry brush cleans better than a wet one, so alternate two brushes.

Choose a fluoride toothpaste that is not too abrasive. Brands that claim to remove tough stains (caused by tobacco and coffee) and whiten teeth can also make the teeth sensitive by removing cementum and exposing the dentin. (Excessive pressure can wear away enamel, too.)

Ideally, you should brush your teeth after every meal and snack. Proper brushing shouldn't take longer than three minutes. Dentists recommend brushing your teeth a minimum of twice a day, after the first and last meals. If you are going to prevent the buildup of plaque, you must interrupt its formation once every 24 hours.

Replace your toothbrushes after three months of use (or before if they are worn out) and after an illness. And never share a toothbrush because you can "catch" tooth decay—that is, you can spread plaque-producing bacteria through saliva.

Develop a plan of attack that you can follow routinely. You may prefer to brush all the outside surfaces first, or you may decide to divide your mouth into quadrants and brush each area inside and out before moving on to the next section.



Using the proper technique for brushing your teeth will help ensure effective cleaning.

- 1) To brush the outside surfaces, set the bristles against the teeth near the gums at a 45-degree angle. Move the brush gently back and forth in short strokes about a half a tooth wide. Clean one or two teeth at a time. Brush along the gum line, too. Use the same technique to clean the inside surfaces.
- 2) For the incisors, you may find it easiest to clean them by holding the brush vertically and using up-and-down strokes.
- 3) Then, with the brush held flat, scrub the chewing surfaces. Be sure to brush every surface, particularly the hard-to-reach ones like the most-often neglected tongue side of all molars and the cheek side of the upper molars.
- 4) Finish up by lightly brushing your palate and tongue (from back to front).

Brushing Teeth With Braces

Having braces may be uncomfortable for a while, but it is ultimately a good thing for your mouth and teeth. People with braces need to be especially careful when brushing because the wires and brackets can trap the bacteria and food particles that cause decay. While brushing techniques used to clean braces are similar to those used to clean teeth alone, paying special attention to wires and brackets is very important.



- 1) Start by cleaning the teeth above the wires of the braces. Set the bristles against the teeth near the gums at a 45-degree angle, then move the brush gently back and forth in short strokes about a half a tooth wide. Clean one or two teeth at a time.
- 2) Then carefully clean the teeth below the wire.
- 3) Next, thoroughly clean the wire and brackets by brushing on top of the wire in a circular motion. Finish by cleaning the chewing surfaces, tongue, and palate as usual.

Because you can't see plaque with the naked eye, you can't know for sure that you have gotten all of it off your teeth unless you use a harmless dye called a *disclosing agent*. Using a disclosing agent occasionally will help you learn how to effectively brush your teeth. You can either chew a disclosing tablet or swish a solution around your mouth. The dye will stain any remaining plaque. Clean the missed areas with your toothbrush, and remember to spend more time on those places the next time you brush. After cleaning your teeth, rinse thoroughly with water or a mouthwash containing fluoride.

Let's See Those Pearly Whites

Sporting whiter teeth is all the rage these days, and there are several ways to get them. There are lots of whitening toothpastes on the market that, with regular and thorough brushing, help remove surface stains to reveal the tooth's natural whiter color. The hydrogen peroxide used in many *bleaching agents*, however, actually makes teeth whiter by bleaching the porous enamel surface. No matter which whitening method you choose, make sure to get a dentist's opinion and supervision before beginning treatment.




How to Floss

Many people use dental floss (a thread usually made of nylon) from time to time like toothpicks—to dislodge bits of food caught between the teeth. But using floss every day between every tooth, below the gum line, and under fixed bridges actually loosens the plaque that a toothbrush can't reach.

Ideally, you should floss whenever you brush. If you floss only once a day, however, do it at bedtime. Wrap about 18 inches of waxed or unwaxed floss around your middle fingers until you have an inch or two of floss between them. Hold the floss taut and guide it between two teeth. Curve the floss against a tooth and slide it gently under the gum line. Scrape it up and down on the surface of that tooth, and then curve the floss on the other tooth and repeat the process.

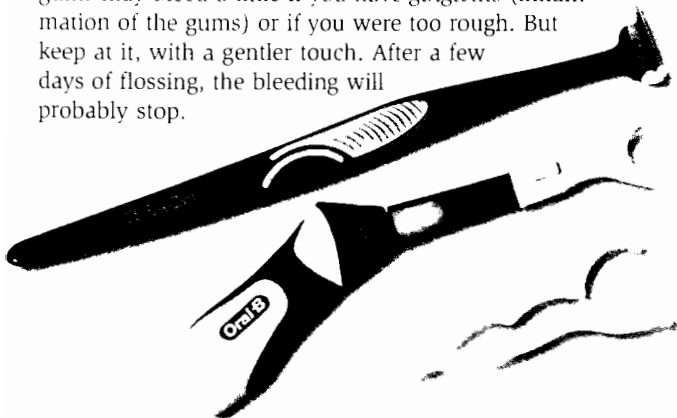
February is
National
Children's Dental
Health Month.



Start at the rear molar on one side of the upper jaw and work to the center. Then move to the other rear molar and work back to the center. Do the same for the lower jaw. Let out more floss as you move along, or replace it if it gets heavy with plaque or starts to fray.

If teeth are so tightly spaced that you can't get the floss between them, use a floss threader and insert it into the space below the contact points. This also works to get under a fixed bridge.

Rinse your mouth thoroughly when you finish. Your gums may bleed a little if you have *gingivitis* (inflammation of the gums) or if you were too rough. But keep at it, with a gentler touch. After a few days of flossing, the bleeding will probably stop.



Flossing reduces your risk of developing gum and bone disease and is so important to oral health that Dr. Michael F. Roizen, author of *Real Age: Are You as Young as You Can Be?*, suggests that flossing every day can add two years to your life expectancy.

Find out whether the water in your home is fluoridated. If it is, try to drink eight glasses of tap water each day and know that while you are replenishing fluids in your body, you are also protecting your teeth from decay.




How Fluoride Helps to Prevent Tooth Decay

Fluoride is a chemical compound that forms when fluorine combines with other elements. If enough fluoride is in the body when teeth are developing, it will react with other minerals to make the tooth enamel extra strong and extra resistant to the acids that cause tooth decay. After teeth are formed, fluoride reinforces enamel and also acts with minerals in saliva to restore enamel in the earliest stages of decay.

Fluoride is present everywhere, in varying amounts. The concentration of fluorides in the soil, water, and plants in certain areas may be lower or higher than in other areas. We can't count on what we eat and drink to give us a consistent, balanced supply of fluoride to ensure that our teeth are strengthened and protected, so we must take steps to expose our teeth to fluoride. You can take fluoride internally or apply it directly to the surfaces of the teeth.

Fluoridation, or adding fluoride to our water supply, is considered to be one of the greatest efforts to protect public health. Studies have shown that supplementing local water supplies with fluoride is an effective and economical way to strengthen people's teeth against dental caries. Many people choose to drink bottled water rather than tap water. Most bottled water, however, does not contain enough fluoride to ward off decay. In-home water filters not only eliminate impurities in tap water, but some filters also eliminate vital fluorides from the water supply.



If the water supply doesn't have enough fluoride to protect teeth, other fluorides can be taken internally (as food or medicine), including liquid and tablet supplements. Since ingested fluoride is most effective on unerupted teeth, it should be introduced at 6 months of age and continue until the second permanent molars erupt. Specific guidelines for fluoride supplementation are available from the American Dental Association.

Erupted teeth also benefit from having fluoride applied directly to the surfaces and hard-to-clean spots. Topical fluoride applications should *not* be swallowed. For people especially susceptible to caries, the dentist or hygienist paints a fluoride solution on the teeth or places gel in a tray inserted temporarily over the upper or lower arch of the teeth. Everyone (unless advised *not* to by a dentist or physician) should use fluoride toothpaste. In fact, the American Dental Association won't approve a toothpaste unless it contains fluoride.

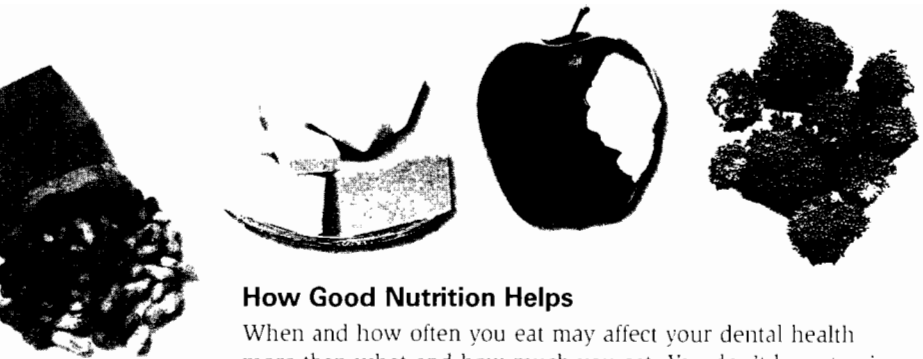Mouthwashes, or mouth rinses, do little more than mask breath odors for 15 or 20 minutes, unless they contain fluoride or an antimicrobial agent that fights tartar and/or plaque. While many mouthwashes do not contain fluoride, they may still have benefits. Read the label to see whether the mouthwash contains the plaque fighters cetylpyridinium chloride and domiphen bromide. Look also for antimicrobial ingredients, such as sodium benzoate, benzoic acid, or chlorhexidine.

Too Much Is Not Always Too Good

It is possible to get too much fluoride, which can cause mottling and pits in the enamel and lead to discoloration of the enamel. This condition, called *fluorosis*, happens in areas where the drinking water has too many fluorides. It doesn't occur where the water supply is artificially fluoridated. The upside of this condition is that although the teeth are stained, they are quite resistant to decay. Bleaching and bonding can help restore the surface of enamel.



If you don't see this sign from the American Dental Association on your toothpaste, the ADA has not accepted it. One of the reasons may be that it doesn't contain fluoride.



How Good Nutrition Helps

When and how often you eat may affect your dental health more than what and how much you eat. You don't have to give up sugar to protect your teeth. If you eat sweet foods and drinks only at mealtimes and faithfully brush and floss your teeth afterward, you can avoid tooth decay.

The extra saliva produced to digest a meal will help wash away or neutralize acids, but eating sugary foods between meals will keep the acid level of the mouth high. If you must snack, choose foods that are low in sugar content: peanuts, popcorn, pretzels, olives, eggs, meats, milk, and plain yogurt. Even better are raw vegetables and fruits (but not fruit juices) because they are high in fiber and require vigorous chewing, which stimulates salivation and cleans the teeth and gums. Snacking before bedtime is harmful because of the reduced production of saliva during sleep. The plaque remains undisturbed on the teeth for hours.

Healthy people
produce about
6 cups of saliva
a day.



Baby bottle tooth decay (BBTD) is a type of caries in children younger than 3 years old caused by using a bottle filled with formula, milk, or fruit juice as a pacifier. When a baby is put to bed with a bottle filled with anything other than water (preferably fluoridated), then the sugars collect around the teeth. The bacteria have all night to produce acids, which destroy the enamel.

Protecting Teeth From Injury

Apart from decay, accidents are the main cause of tooth injury and loss in children.

Environmental Hazards


Many teeth have been knocked out because of a jump off a swing, a shove into a drinking fountain, a fall at the swimming pool, and poor footing on a wet tree trunk. Automobile crashes or sudden stops account for more tooth injuries. Everyone should take safety precautions to avoid these kinds of accidents. Don't run or climb on wet surfaces. Watch where you're going. Wear a seat belt.

Tooth loss often has an indirect cause. Radiation of the head or neck, such as in treatment for cancer, can destroy the salivary glands. The acids created by certain bacteria remain on the teeth, so decay sets in with a vengeance. Blood disorders affect the body's ability to fight infection, making a person susceptible to periodontal disease.

Mouth Guards

Everyone who plays active sports that are potentially dangerous to the face and head should wear a mouth guard. This device helps prevent teeth from getting chipped, fractured, or knocked out and protects the lips, tongue, and cheeks. The mouth guard cushions the impact of a blow or fall that might cause a concussion or broken jaw and distributes the pressure throughout the jaw.

Often, people cope with stress by grinding their teeth (a habit called *bruxism*). The constant heavy pressure can wear down and loosen teeth. With regular examinations, a dentist can tell whether a person has developed this habit and can recommend treatment.



Be careful not to burn your mouth when inserting the guard after heating it.

Wearing a mouth guard is required in many sports, such as football, basketball, boxing, lacrosse, and ice hockey. People who surf, skateboard, ride scooters, rodeo, or participate in gymnastics should also protect their teeth by wearing mouth guards.

You can buy mouth guards in a store, or a dentist can make them specifically to fit your mouth. Stock mouth guards are available at sporting goods stores. To keep these in place, you have to clench your teeth, which may interfere with your breathing. "Boil-and-bite" mouth guards are made with moldable plastic that can be softened in warm water. The plastic then takes the shape of the teeth. To get the best fit and comfort, ask your dentist to make one from an impression of your teeth.

Usually, a mouth guard is worn on the upper teeth, but sometimes people may want one to cover the lower teeth, too, if they have braces. Whatever mouth guard you choose, be sure it fits well and that you are able to speak and breathe easily while wearing it.




Face protectors are absolutely necessary if you play a position in a sport that puts you directly in the line of something that can hurt your teeth or face. Baseball catchers and hockey goalies fall in that category.

Your Tooth Is Injured . . . Now What?

Injuries range from a tiny fracture in the enamel to broken and avulsed (knocked out) teeth. You might not see the fracture but will feel discomfort when chewing or if a sharp edge of the enamel irritates your lips or tongue. Seek treatment before the tooth is permanently damaged. If you experience sensitivity to changes in temperature, or find loose tooth fragments, call your dentist immediately. Treatment may include capping, bonding, root canal therapy, or extraction.

If you break your tooth, try to gather the broken pieces. Rinse your mouth with warm water. Take the pieces to the dentist, who will determine whether they can be bonded back onto the tooth. If swelling occurs, apply a cold compress to the face at the swollen area.

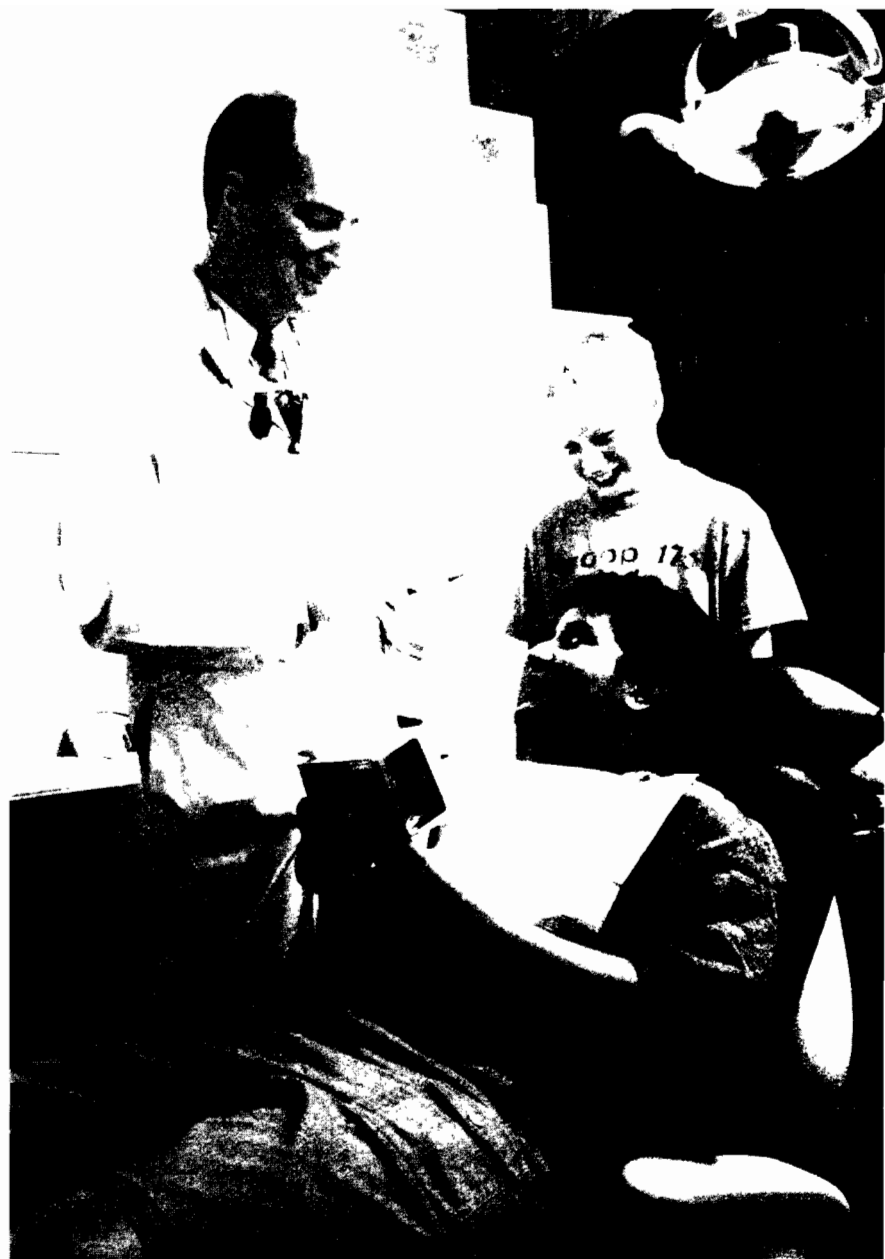An avulsed tooth can be successfully replanted in the socket if you act fast. The first 30 minutes after the tooth is knocked out are critical. Hold it by the crown—not by the roots as you may destroy any surrounding tissue. Rinse it in milk, if available, or hold the tooth under cold running water, and get to a dentist immediately.



The main reason a replanted adult tooth might be lost is due to root resorption. This happens when the body rejects the roots and absorbs them over time. It is important that the dentist take an X-ray film of the tooth at least six months after it has been replanted to make sure that the roots are still intact.

If you can't replant the tooth, carry it to the dentist under your tongue or between your cheek and gum. If you are worried about swallowing the tooth, cover it with milk in a container or roll it up in a wet towel. *Do not allow the tooth to dry.* Go directly to the dentist—and don't forget the tooth!

If a permanent tooth gets knocked out, the trauma may cause damage to the nerves and blood supply, and even the alveolar bone. Often, the pulp dies. A dentist can determine whether root canal therapy will be necessary. If a primary tooth gets knocked out, the dentist may decide to insert a space maintainer to keep the teeth on either side of the space from moving together before the permanent tooth erupts.



At the Dentist's Office

Making a trip to the dentist is the best way to pinpoint problems in your mouth. Don't wait until you feel pain to schedule an appointment, and don't worry—visiting the dentist regularly is a gift you can give your mouth!

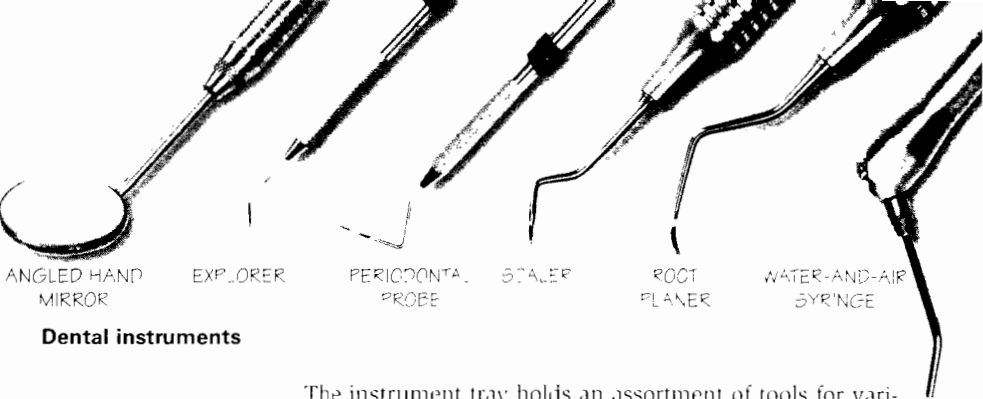
Equipment and Materials

A dentist's office is full of interesting tools, equipment, and supplies that are used to help keep teeth healthy. The dental unit, which may be freestanding or attached to the examining chair, holds various pieces of equipment: an adjustable overhead spotlight, which directs a high-intensity beam on the mouth; a saliva ejector, or small suction pump placed in the mouth to keep it dry during treatment; air hoses for low-speed and high-speed rotary hand pieces or drills; and an instrument tray.

Other equipment includes an autoclave for sterilizing instruments, an X-ray machine, and an ultrasonic cleaning machine, which emits high-speed sound waves that vibrate the tartar deposits off the teeth.



This ultrasonic cleaner sterilizes dental instruments.



ANGLED HAND MIRROR

EXPLORER

PERIODONTAL PROBE

SCALER

ROOT PLANER

WATER-AND-AIR SYRINGE

Dental instruments

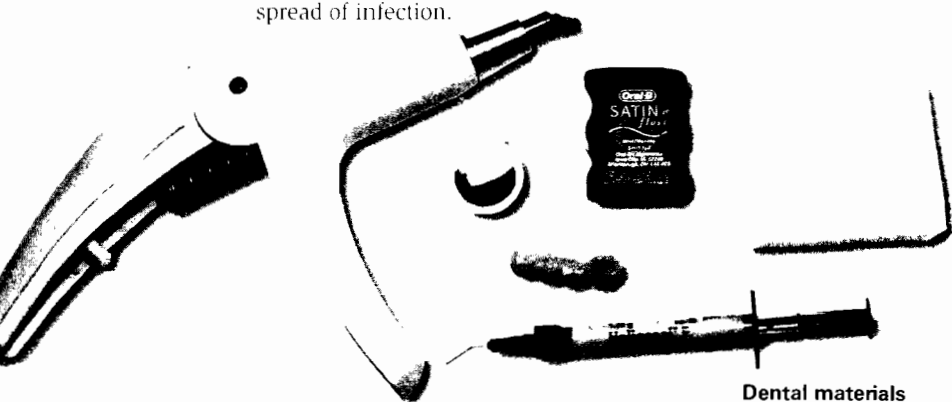

The instrument tray holds an assortment of tools for various tasks. The *angled hand mirror* helps the dentist examine hard-to-see tooth surfaces. The *explorer* is a metal probe with a curved, pointed end that is used to poke around in crevices and cavities. The *periodontal probe* has a straight tip marked like a ruler and is used to measure the depth of "pockets," or spaces where the gum has pulled away from the teeth. A *scaler* is a narrow-bladed instrument for scraping plaque and tartar off the crown; a *root planer* scrapes the buildup off the roots. A *water-and-air syringe* is for flushing debris that has just been scraped off the teeth and for cooling down the teeth during drilling.

Some other tools include tweezers, a polisher, hypodermic syringes for injecting anesthetic, and high- and low-speed rotary hand pieces with their attachments: drilling and grinding burs, and cleaning heads.

Rotary tools

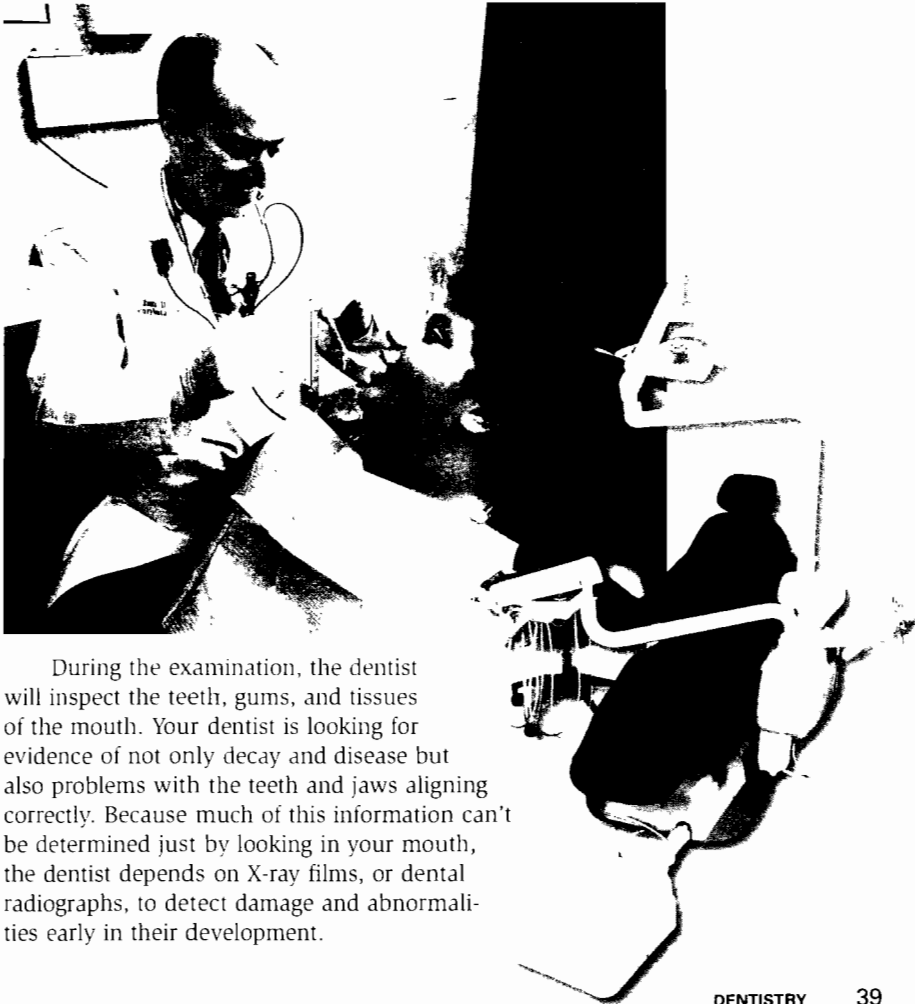
Dental materials include dental floss, polishing pastes, filling materials for cavities, gauze squares, fluoride varnishes, sealants, and substances for making dental impressions and artificial teeth. Certain dental supplies, such as disposable gloves and surgical masks, are used to prevent and control the spread of infection.



Dental materials

The Examination

The main purpose of dental care is the prevention of tooth decay, gum disease, and disorders affecting oral health. Because decay and disease get worse if left untreated, you should get your teeth cleaned and examined every six months. To prevent dental and medical complications that can result from certain procedures, the dentist must know your medical history, especially whether you have conditions such as asthma, allergies, immune system problems, or infectious diseases.



During the examination, the dentist will inspect the teeth, gums, and tissues of the mouth. Your dentist is looking for evidence of not only decay and disease but also problems with the teeth and jaws aligning correctly. Because much of this information can't be determined just by looking in your mouth, the dentist depends on X-ray films, or dental radiographs, to detect damage and abnormalities early in their development.

The Radiograph

The X-ray is a form of electromagnetic radiation that can penetrate bone and soft tissues. Dense tissues like teeth and bone absorb more radiation than soft tissues like cheeks and gingiva.

These substances cast shadows on the film when the X-ray penetrates them. Teeth and bone will cast more of a shadow than gums, but they will appear lighter because the film image is a negative. Caries, abscesses, and bone loss appear darker than normal. Metal crowns and fillings look like white patches on the film.



View from a bitewing radiograph



Radiographs are taken inside and outside the mouth, depending on what views are required. The *bitewing films*, taken inside the mouth, show only the crowns and parts of the roots of two or three pairs of opposing upper and lower teeth. These radiographs reveal decay between adjacent teeth and under restorations (materials that replace tooth structure and function), bone loss from periodontal disease, and ill-fitting fillings. Bitewing radiographs are typically taken at 12-month intervals.



Digital bitewing

Dentistry Goes Digital

Many dentists now use digital radiography instead of the traditional film-based X-ray for capturing radiographic images of a patient's mouth. Doing so allows dentists to obtain a more extensive view, in less time, and with more flexibility for storing and sharing information.

The *periapical films*, also taken inside the mouth, show the entire tooth, from the crown to the root and including some of the periapical bone, which surrounds the root tips. These radiographs indicate the condition of the root and bone; missing, *impacted* (teeth that haven't erupted and remain fully or partly in the bone), or fractured teeth; and cysts, tumors, and abscesses.



On this panoramic X-ray, tooth decay and abscesses show up as darker patches.

A *full-mouth survey* is a combination of 14 or more periapical and bitewing films showing all the teeth (crowns and roots) as well as all the surrounding alveolar bone. This set of films is taken as needed for a specific diagnosis, or at intervals of about every three to five years.

The *occlusal radiograph* is another film taken inside the mouth. It shows the full arch of the bite, from an upper or lower view, and is useful for locating abscesses; other problems in the jawbone, such as extra, unerupted teeth; and stones in the salivary gland ducts. Most people don't need this kind of radiograph except for special instances.

The *panoramic radiograph* is a wide view that shows all structures in the lower half of the face: upper and lower jaws, sinuses, and cheek bones. Dentists use it to evaluate the general condition of the mouth and to detect jaw fractures, possible tumors, missing teeth, third molars, and "hidden" impacted teeth. This radiograph is taken outside the mouth.

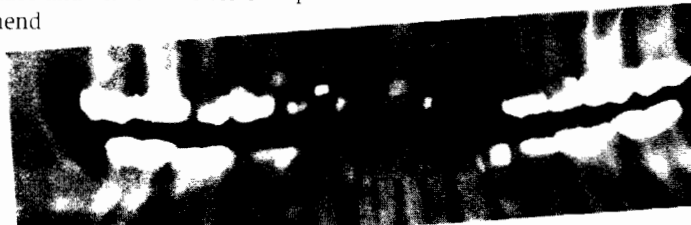A special X-ray machine automatically moves in a semicircle around the face and makes a series of exposures. Many dentists recommend making this kind of radiograph every five years.

Full-mouth survey




Occlusal radiograph

Panoramic radiograph

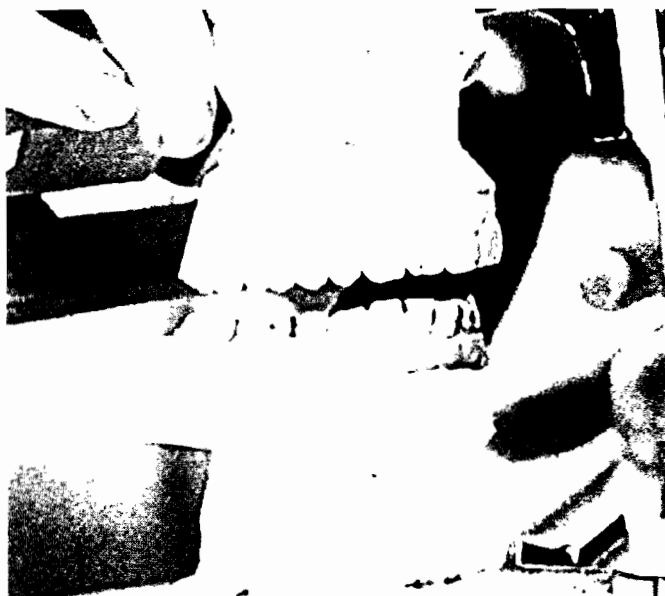


Some people worry about their exposure to radiation when X-ray films are made. When carefully used, X-rays are not dangerous; however, dentists take certain precautions to reduce the risk and the exposure. They use high-speed film, timers, and filters to reduce the exposure time and eliminate unnecessary radiation. They also cover the patient with a lead apron during the X-ray procedure to protect the body, particularly the reproductive organs, from exposure. This apron should have a thyroid collar to protect the thyroid gland, which easily absorbs radiation. Dentists also follow recommended guidelines about how often to make X-ray films. Finally, more and more dentists are using *digital radiography*, which greatly reduces the exposure to radiation.



The Dental Model

After the dentist examines the mouth and studies the radiographs, he or she may decide to make a three-dimensional model of the teeth and jaws. This record is important for determining the exact position of the teeth and the relationship between the jaws, particularly if orthodontics (such as braces) or extensive prosthodontic repairs (such as dentures) are necessary.





First, an impression tray that fits the contour of the dental arch is filled with a sticky impression material that is much like modeling clay.

Then the tray is pressed over the teeth of one jaw and the material is allowed to set for a few minutes until it gets firm. The tray is removed, and the process is repeated for the other jaw.

Later, a dental technician will cast models of the jaws by pouring dental stone into the impressions, or molds, and letting it harden.

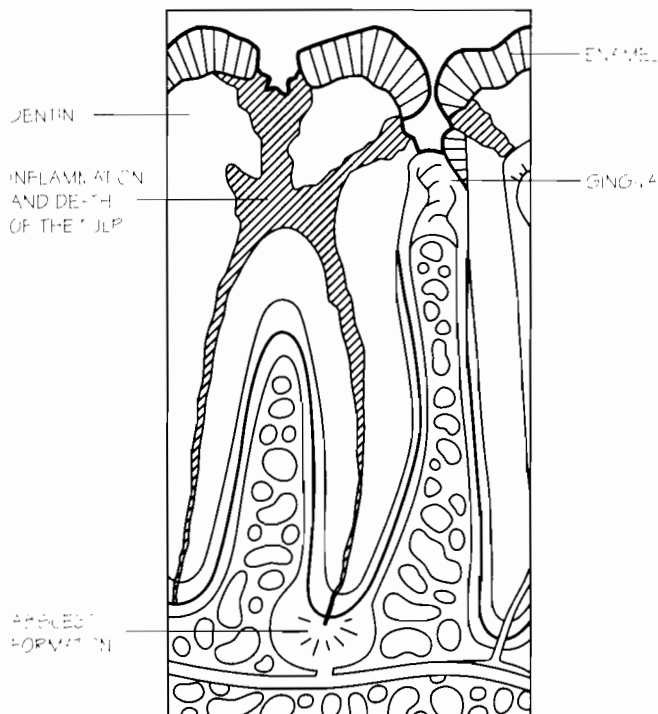
Then the models are mounted on an *articulator*, a hinged device that allows the dentist to open and close the jaws and study the bite, or *occlusion*.

Checking for Decay

To check for decay, the dentist uses a small mirror and explorer to examine the crown of each tooth. When the probe is poked into the chewing surface, it will stick or be difficult to remove if caries is present. A white spot on the tooth indicates that *decalcification* (softening of the enamel due to loss of calcium salts) has begun. A cavity, or hole, is a sign that decay has destroyed the enamel and penetrated the dentin.

Decay and cavities tend to occur in specific areas of the teeth where food and bacteria are easily trapped: in grooves and fissures on the molars and bicuspid; on the surfaces between adjacent teeth (called *proximal surfaces*), especially where one tooth touches another; and in the *sulcus*, the V-shaped depression inside the cuff of gum tissue that forms around the base of the crown.

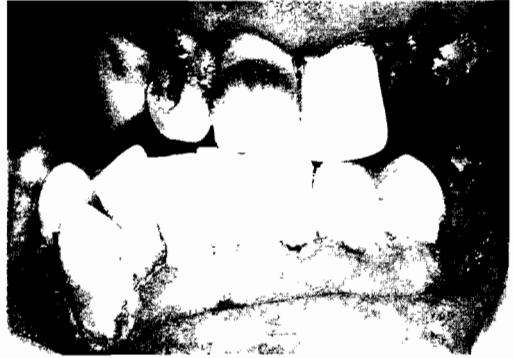More and more dentists are using a laser procedure that gives a digital reading of the progression of decay and can detect it at a very early stage. Early detection of decay through new dental technologies can help save teeth.



Left unchecked, a small cavity can expand into the root of the tooth.

Checking for Gum Disease

In the past, tooth decay was the main reason people lost their teeth. But today, because fluoridation has helped prevent decay, the number one reason for tooth loss in adults younger than 30 is periodontal disease. Genetic factors are the leading cause of periodontal diseases, but other factors can increase the risk. Medical conditions such as diabetes or HIV, smoking or chewing tobacco, poor nutrition, impacted teeth, and ill-fitting restorations can make you more vulnerable to periodontal disease.



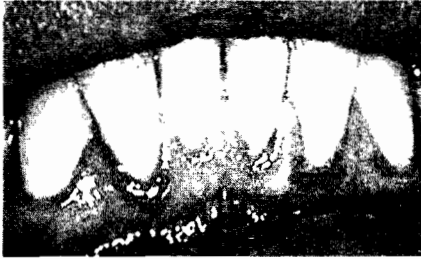
Badly diseased gums

The dentist can often tell by a visual examination of the mouth whether you have periodontal disease, but he or she also depends on X-ray films of bone loss and a probing assessment to determine the degree of activity or severity. With a periodontal probe (manual or automated), the dentist will test the gums for attachment, depth of the sulcus or pocket, tooth mobility, bleeding, and bone destruction.

If you have any of these symptoms of periodontal disease, see your dentist:

1. Gums that bleed when you brush your teeth
2. Gums that are tender, swollen, or red
3. Gums that no longer adhere to the teeth
4. Persistent bad breath
5. Pus in the gingival crevice
6. Loose teeth
7. A change in your bite
8. A change in the way your partial dentures fit

There are four stages of periodontal disease.



Gingivitis



Advanced periodontitis

- The first stage is **gingivitis**, the inflammation of the gums. Diligent oral hygiene and routine professional cleaning can improve the symptoms and heal the gums.
- The second stage is **early periodontitis**. The tissue lining the sulcus becomes inflamed and swollen; the sulcus deepens, providing a perfect place for bacteria to multiply; and damage to the tissue extends as far as the alveolar bone.
- In the third stage, **moderate periodontitis**, the pockets deepen even more, harmful bacteria thrive, the periodontal ligament and alveolar bone are inflamed, and bone dissolves.
- In the fourth stage, **advanced periodontitis**, bone loss is so severe that the tooth is loose in its socket and eventually will fall out.

Treatment varies depending on the stage of the disease, from simple tartar scraping and tooth polishing, to removal of damaged tissue with a spoon-shaped instrument, to scraping and planing (smoothing) the tooth root, to laser treatment, to gum surgery. The dentist will sometimes refer a patient with periodontitis to a specialist called a *periodontist*.

Checking for Oral Cancer

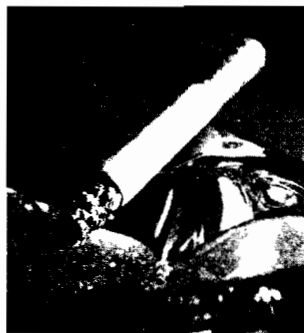Of all the places in the body where cancer occurs, the mouth is the seventh most frequent. Certain oral cancers, such as cancer of the tongue, are deadlier than colon cancer, breast cancer, or Hodgkin's disease. The main victims of oral cancer are smokers, former smokers, chewing tobacco users, and heavy drinkers of alcohol. Survival rates improve dramatically if the oral cancer is detected and treated early.

The most common place for the cancer to develop is on the lips (particularly the lower lip). This is often the result of regular exposure to the sun and mostly affects light-complexioned people. Other areas of oral cancer, in order of frequency, are the sides and back two-thirds of the tongue, floor of the mouth, gingiva, roof of the mouth, and insides of the cheeks.

Cancers of the tongue and floor of the mouth are quite deadly because they often spread (*metastasize*) to the lymph nodes and then to other parts of the body. The opposite happens, too; sometimes cancer in other parts of the body spreads to the mouth and causes tumors.

You should pay attention to the following warning signs and let your dentist know if you have any of these symptoms:

1. A sore in or around the mouth and neck areas that does not heal within two weeks
2. Unexplained bleeding in the mouth
3. Numbness or loss of feeling in any part of the mouth
4. Unexplained pain or soreness in the mouth
5. Swelling on the lips, tongue, roof of the mouth, or neck
6. Difficulty chewing or swallowing food
7. A lump or thickening in your cheek that you can feel with your tongue
8. A white or red patch on your tongue, gums, or soft tissues in the mouth



If the dentist suspects cancer, the dentist or an oral surgeon will perform a screening procedure called a *biopsy*, which is the surgical removal of a tissue specimen to determine what kinds of cells are present. An oral pathologist will examine the tissue under a microscope and report the findings to the dentist or oral surgeon. If the cells are cancerous, then the treatment may require extensive surgery and/or chemotherapy or radiation therapy. If surgery is necessary, an oral surgeon may remove part of the jaw, tongue, or roof of the mouth.

Cancer treatments (especially radiation and chemotherapy) reduce the body's ability to fight infection. In some cases, the bone tissue in the jaw is destroyed. The dentist will take steps to reduce that risk by treating tooth and gum problems *before* radiation therapy. One serious side effect of radiation of the head or neck is damage to the salivary glands. If the glands are destroyed, the mouth dries out, swallowing becomes difficult, and tooth decay sets in.

Blood, Sweat, Tears . . . and Spit?

Our bodily fluids can say a lot about us: a high white blood cell count can indicate infection; lack of sweat on a very hot day can signal heatstroke; tears can help flush an object from the eye. But what can saliva tell us about the body's general health? More than you might think.

Saliva improves the taste of your food. The body just can't taste food that is dry. Saliva provides a natural lubricant that brings out the cheese in your macaroni, and yes, even the Brussels in your sprouts.

Saliva protects your mouth and teeth. By providing a protective layer between your mouth and the food you eat, saliva can help maintain healthy cells inside your mouth. It allows tooth-damaging food particles to float away, helping protect your pearly whites from decay. Also, the pH of saliva closely resembles that of your teeth, so it helps maintain the mouth's acidity and protects teeth from decay.

Saliva helps in digestion. You might not be thinking about digestion at the dinner table, but as soon as you take a bite, the saliva in your mouth is getting to work. The mucus in saliva helps bind food and make its trip to the stomach easier.

Saliva improves your speech. The natural lubricant that saliva supplies to your mouth helps keep you from getting tongue-tied.

Saliva helps keeps your breath fresh. Saliva contains a natural enzyme that slows bacteria production. When you sleep, the body produces less saliva, so bacteria—and the smells that go with it—are free to build up in your mouth. And you wondered where you get that morning dragon breath!

Scientists have developed many tests using human saliva to diagnose various illnesses, including certain cancers and viruses. Dentists use saliva tests to check a patient's susceptibility to caries.

Treating Teeth

If caries has not penetrated the enamel, the dentist may apply a plastic “pit-and-fissure” sealant to prevent bacteria from attacking the enamel on a bicuspid or molar. He or she may also paint fluoride on the smooth surface of the tooth, with repeated topical applications over time, in the hopes that the enamel will remineralize.

Decayed and Broken Teeth

If caries has penetrated the dentin and created a cavity, the dentist will remove the decay and insert a filling. If the damage is extensive and the tooth is brittle, he or she will restore the tooth with an artificial crown. Once decay has reached the pulp, the dentist or a specialist (an *endodontist*) will perform root canal therapy to remove the pulp and save the tooth. As a last resort, the dentist will take out the tooth.

If the tooth structure is still sound, the dentist will fill the cavity with one of several materials: silver amalgam, gold, composite, glass ionomers, or porcelain. The choice depends on various factors such as the location of the infected or broken tooth, the size of the decayed area, the strength of the filling material, aesthetic concerns, and cost.

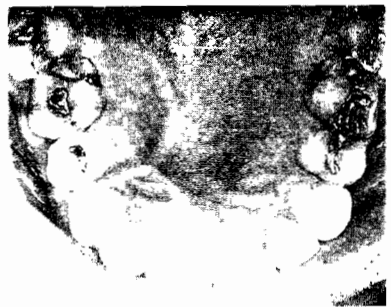Silver Amalgam. Silver amalgam is a mixture, or *amalgam*, of silver, mercury, and trace metals. Dentists have used it for more than a century to fill cavities in the grinding and chewing surfaces of molars and premolars. Because of the filling’s dark color, dentists prefer to use it in the inconspicuous back teeth and not on the front teeth. If properly formed, silver amalgam will completely seal the cavity. It is strong and durable, easy to insert in one office visit, cost-effective, and biocompatible—that is, it won’t irritate the living tissues in the teeth and gums.



Decayed tooth



Tooth with an artificial crown



Teeth filled with silver amalgam

Silver amalgam has some disadvantages. It is brittle and requires adequate tooth support to hold it in place and keep it from getting chipped or shattered. Unlike the other kinds of fillings, silver amalgam is not attached or cemented to the tooth, although sometimes the two may be “bonded.” The cavity is undercut to lock in the filling when it hardens. Sometimes the filling becomes loose and falls out, or expands, causing the tooth to crack. The amalgam may leak at its margins (where the metal meets the tooth) and discolor the gums or enamel.

Gold (Foils, Inlays, and Onlays). If decay has destroyed large areas of the tooth, the dentist may recommend a gold filling, which is stronger than silver amalgam. Unlike the silver filling, gold is not brittle and can actually strengthen the tooth structure. It is lighter in color than silver amalgam and does not stain the enamel. However, gold does look artificial on visible tooth surfaces and is much more expensive than other filling materials.

Most solid gold fillings—called *inlays* or *onlays*—are cast from a mold of the cavity and cemented in place. These aren’t really fillings because they are made in a dental laboratory. An inlay is set between the walls of tooth structure, but like a wedge, it can split the tooth if too much pressure is exerted to force it into position. With an onlay, gold “lays over” the natural cusps of the tooth, which have been cut down, and forms a protective bond.

Inlays, onlays, and crowns are also used to restore broken or fractured teeth. Unlike the inlay or onlay, which holds the tooth together from the inside, the crown completely or partially covers the tooth and holds it in place from the outside. If part of the tooth is broken off and the remaining structure can’t support a filling, inlay, or onlay, then the dentist will “cap” the tooth with a crown.

The cast gold fillings, particularly the onlay, are very effective but quite expensive. They also require two or three office visits before the filling can finally be inserted. Between appointments, the patient must wear a temporary filling to protect the cavity from contamination and fracture. Although gold offers a better restoration than other filling materials, many patients decide against it because of the expense, the inconvenience, and its unnatural look on the teeth.



Before composites



After composites

Composite techniques are difficult, and certain procedures must be followed so that the composites will work. For instance, it is very important to keep saliva or blood off the tooth once it has been readied for bonding. Dentists often say that placing composites is "technique-sensitive." That means that every step must be done with great care for a good final result. If composites are not done properly, leakage, tooth pain, damage to the nerve, and new decay may result.

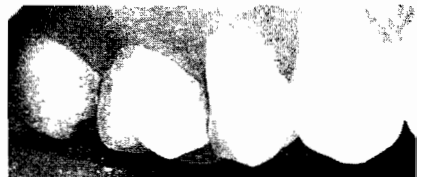Composite. Composite is a mixture of plastic resin and fine reinforcing particles that is naturally white and can be shaded to match the color of a tooth. With recent developments, these tooth-colored fillings can last about as long as metal ones. The composite adheres to the surface of the tooth, so it can be painted on a discolored tooth or bonded to malformed or misshapen teeth. This allows the dentist to radically improve upon appearance of a damaged tooth and also make it stronger by bonding it together.

Anyone may have unusual sensitivity to any dental materials, so dentists may have to experiment to find out what works best for an individual patient.

Porcelain. Porcelain is a ceramic material that, like the composite, can be colored to match the color of the natural teeth and is suitable as a filling and as a crown on visible surfaces. Because of its durability, longevity, and resistance to staining, porcelain is superior to composite; however, it is more brittle than gold or silver amalgam. Like gold fillings, it requires several office visits and is, therefore, more expensive than the amalgam or composite materials.



Before porcelain



After porcelain

Missing Teeth

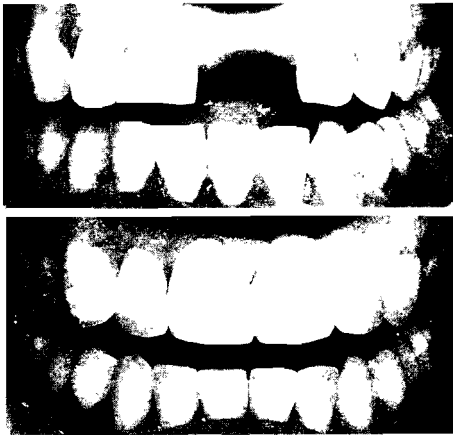The main cause of tooth loss is periodontal disease, but dental caries, injury, congenital problems (problems that exist since birth), and tumors can all damage the tissues in the mouth and contribute to this serious condition. Missing teeth should be replaced immediately, except for the third molars, or wisdom teeth. It isn't necessary to replace primary teeth, but the spaces must be maintained so the permanent teeth can erupt in the proper alignment.

Most people are eager to replace missing teeth to improve their appearance, but there are more critical reasons for replacing them: to restore chewing function and fix a bad bite, to prevent damage to the remaining teeth, to prevent adjacent teeth from drifting into the spaces and getting out of alignment, to support the muscles that control facial expressions, and to prevent alveolar bone loss. These factors can lead to total tooth loss, which can actually cause the face to collapse.

The dentist, or a specialist called a *prosthodontist*, will decide what kind of treatment is required on the basis of how many teeth are missing and how healthy the adjacent teeth and gums are. A fixed partial denture, or *bridge*, is used to replace one or more missing teeth as long as there are healthy teeth on either side of the space. The good teeth are crowned to support and connect the artificial tooth.

If some of the adjacent teeth are not strong enough to support the bridge, then the dentist will make a removable partial denture, which depends in part on support from the gums and bones of the jaw. If all the teeth are missing in a dental arch, a full removable denture is necessary.

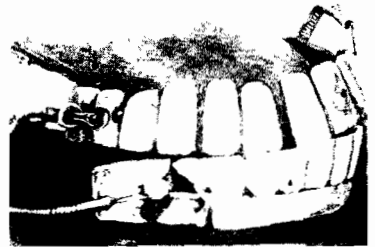Complete dentures—substitutes for natural teeth—have their drawbacks. People sometimes complain that chewing is more difficult, that the dentures don't fit properly and make clicking noises when they talk or eat, and that wearing them makes them gag. So do your best to keep your own teeth.



Dental *implants* are another way to deal with missing teeth. Titanium anchors inserted into the jawbone act as artificial replacements for tooth roots. Then, a bridge, denture, or tooth is attached to the implant.

Implants can be a good idea no matter how many teeth are missing—from just one tooth, to all the teeth. They can replace missing teeth if the bone is healthy, thereby helping to keep the teeth on either side healthy, too. They are also used when all the teeth are missing to help give full dentures more stability. Implants are a popular option because they do not damage adjacent teeth.

George Washington had lost all but one tooth by the time he became president. He wore several sets of false teeth, but they were never made of wood, as we commonly hear. His dentures were fashioned from gold, hippopotamus ivory, elephant ivory, walrus ivory, cattle teeth, and human teeth.

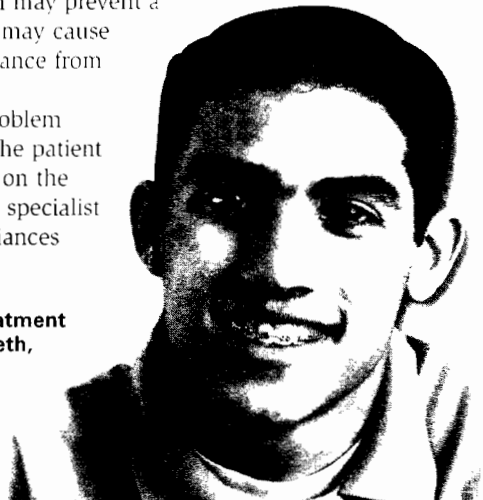


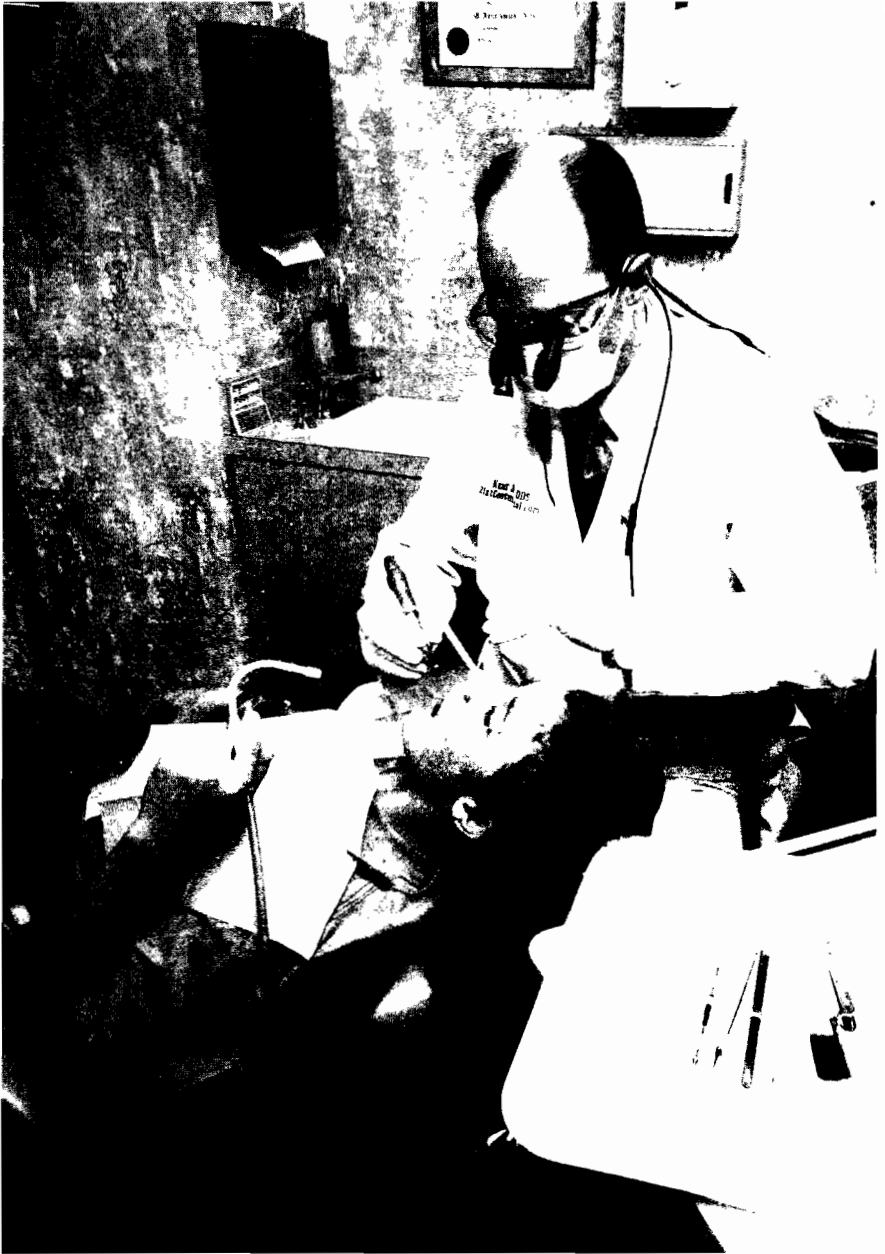Misaligned Teeth

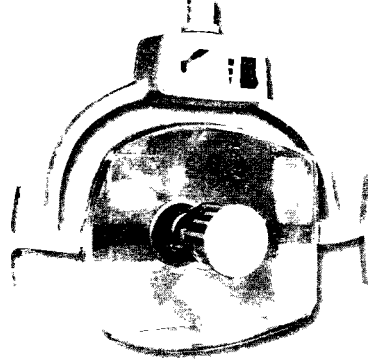
Teeth that are crowded or crooked are difficult to clean, which makes them prone to tooth decay and gum disease. Missing teeth, misaligned teeth, and abnormal jaw structure affect the way the teeth in both jaws meet, or *occlude*. Malocclusion is a bad bite. It can cause the teeth to wear down unevenly. It may place stress on the tissues, bones, and joints in the face, causing pain or damage. Misaligned teeth may prevent a tooth from erupting (impaction), or they may cause one to grow out too far (for lack of resistance from an opposing tooth).

Sometimes the dentist can fix the problem by extracting a tooth. Usually, however, the patient is referred to an *orthodontist*. Depending on the degree of tooth movement necessary, the specialist will recommend fixed or removable appliances such as braces and retainers.

Orthodontists prescribe braces for the treatment of problems like crooked or misaligned teeth, buck teeth, and overbite or underbite.







Careers in Dentistry

The dentist you routinely see for checkups, cavity fillings, tooth extractions, and cleaning is the *general dentist*. He or she is trained to care for the teeth, mouth, and jaws and can recognize and treat conditions that affect not only the mouth and supporting structure but also the rest of the body. The primary focus of a general dentist is operative dentistry, which is concerned with fixing, repairing, or restoring teeth. The general dentist is licensed to prescribe certain drugs and to administer anesthetics. Often, the dentist is the first doctor to diagnose oral cancer or AIDS.

If someone requires special treatment such as braces, dental implants, or complicated root canal therapy, the dentist may refer that person to a specialist who has extra training for that treatment.

Specialties in Dentistry

The American Dental Association recognizes nine dental specialties. Each focuses on a specific type of dental treatment or kind of patient. Specialists who have met the educational requirements for that specialty can choose to limit their practices to their specialty, or they can also perform general dentistry. However, general dentists who practice a specialty may not limit their practices to that specialty.

Dental Public Health

Public health dentists focus on the prevention and control of dental diseases on national and international levels and promote oral health care through educational programs in communities and institutions. They generally work for government agencies such as the United States Public Health Service, the military, hospitals, and universities. Dentists in this specialty study trends in dental disease and related disorders and report this information to other dentists and to the general public. A specialist in dental public health must earn an advanced degree and complete a dental public health residency.

Endodontics

An endodontist cares for the inner parts of the teeth. This specialist is concerned with the prevention, diagnosis, and treatment of disorders of the dental pulp and tissues surrounding the root of the tooth. The endodontist is an expert in pulp capping, root canal therapy, surgical procedures such as root amputation, and bleaching (for teeth discolored as a result of pulp damage).

Oral Pathology

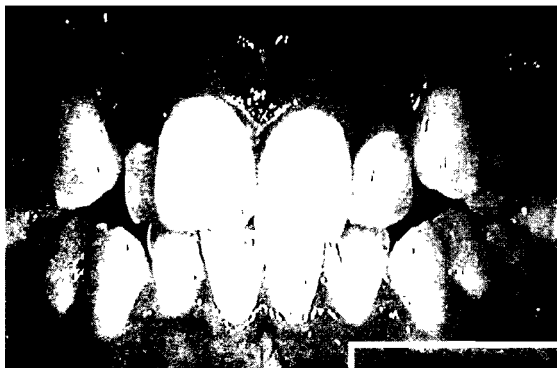The oral pathologist studies tissues from the mouth and teeth and diagnoses oral diseases such as tumors and cancers. He or she is a resource person, or consultant, for general dentists and specialists. Although some oral pathologists treat patients referred by general dentists, most work in research environments in laboratories, hospitals, and dental schools.

Oral and Maxillofacial Surgery

This specialty involves the diagnosis and surgical treatment of diseases, injuries, and birth defects affecting the mouth, face, jaws, and neck. The oral surgeon performs complicated tooth extractions (for example, impacted third molars) and biopsies; reconstructs cleft lips, cleft palates, and malformations of the facial bones; and replaces teeth with dental implants. He or she is trained to administer sedatives and anesthetics that most dentists are not permitted to prescribe.

Oral and Maxillofacial Radiology

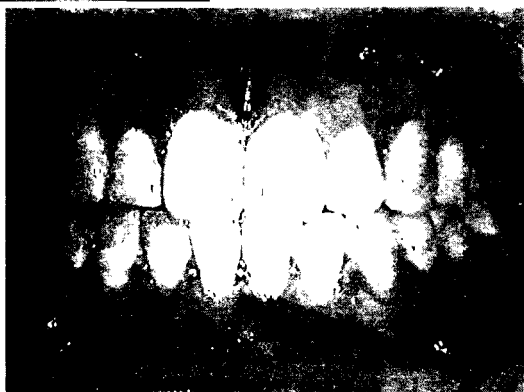This newly recognized specialty provides advanced imaging for patients who have complex problems. The general dentist (or other specialist) usually provides the patient with radiographic services. However, a patient may sometimes need advanced imaging techniques that require sophisticated and expensive equipment. Like oral pathologists, oral and maxillofacial radiologists may examine patients referred to them by other dentists or by physicians. Many of these specialists work in institutional settings such as dental schools, where they teach and also conduct research.



**Orthodontics—
before and after**

Orthodontics and Dentofacial Orthopedics

An orthodontist corrects malocclusions (bad bites) and straightens crooked teeth, crowded teeth, and buckteeth. This specialist uses fixed appliances such as braces to slowly reposition teeth and removable devices to change the structure of the jaws or keep teeth in place (with a retainer).

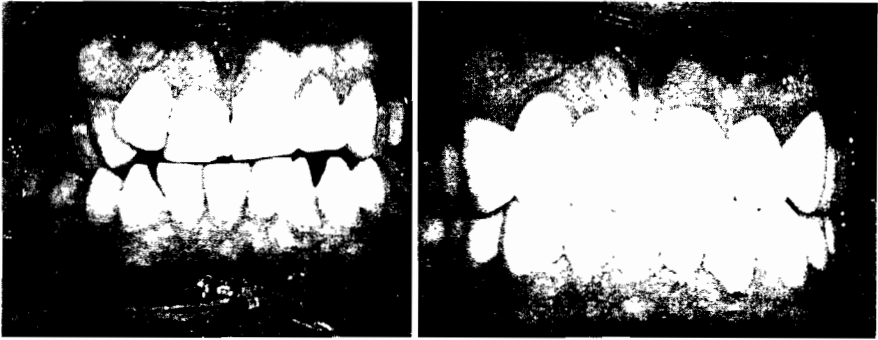

Pediatric Dentistry

In general, a pediatric dentist is one who treats children and teenagers, although some also care for mentally and physically challenged adults. Pediatric dentists study the growth and development of children's facial structure and teeth, and they are trained in easing the fears of children who are afraid of going to the dentist.

Periodontics

Periodontics is the specialty concerned with tissues around the teeth—the gingiva and supporting bone. The periodontist prevents, diagnoses, and treats the gum disease caused by plaque, and uses nonsurgical treatments such as scaling, root planing, and medication application to reduce the quantity of harmful bacteria and smooth the surface of the root (to slow the rate of bacterial regrowth). Periodontist also perform surgical procedures to remove gum tissues and eliminate pockets, which trap food and the bacterial plaque. Additionally, they often place implants to restore missing bone and teeth.



Prosthodontics—before and after

Prosthodontics

The purpose of this specialty is to replace all or parts of damaged or missing teeth in order to restore the normal chewing function of teeth and to improve the occlusion, or bite; to prevent further damage; and to improve appearance. Prosthodontists design, make, and fit inlays, crowns, bridges, partial and full dentures, and implants.

Maxillofacial prosthodontists work with oral surgeons to replace lost parts of the face (such as noses).

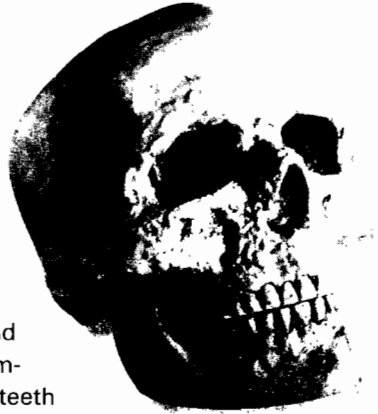

Tooth Sleuths

All humans have a set of mystery-solving clues right under their nose. Just like DNA evidence or fingerprints, the arrangement of a person's teeth can be useful in *dental forensics*—the science of identifying disaster and crime victims, and even the suspects, from evidence found in the mouth.

As the hardest, most durable parts of the body, human teeth can often withstand a major impact or fire without a lot of damage. And although cavities are proof that teeth can decay, they do not decompose as quickly as the rest of the body. By comparing a set of teeth to existing dental X-rays, scientists can be positive if the two are a match, which can mean closure to a grieving family trying to identify the remains of loved ones killed in a plane crash or other disaster. When dental records are not available, scientists can compare digital photographs of the teeth to a picture of the smiling person. In fact, three-dimensional computer technology can even reconstruct a person's facial features based just on skeletal remains.

Before forensic dentistry was introduced, identifying disaster victims could be done by DNA testing—which could take up to six weeks. Now it can be almost immediate, and it can get even faster. The FBI is developing a national dental identification database that can compare thousands of dental records and return possible matches, much like the Automated Fingerprint Identification Systems that many police and government agencies use. Using quick identification techniques made possible by forensic dentistry can have positive applications in the real world. For example, matching bite marks on a victim's body to a suspect's teeth can help put criminals behind bars.



Dental identification is not new to the United States. During the Revolutionary War, for example, Paul Revere was able to identify a colonel who was killed in battle by the ivory and wire bridge Revere had made for him.

Dental Auxiliaries

It takes a team to care for your mouth. After you, the general dentist has the overall responsibility for your oral health. But dentists also depend on several other people to help with diagnosis and treatment.



Dental hygienist

Dental Hygienist

The dental hygienist, a specially trained and licensed dental nurse, provides the most important preventive maintenance services: dental prophylaxis (teeth cleaning), application of topical fluorides and sealants, and oral examination for decay and periodontal disease. The hygienist takes radiographs, records case histories, charts dental conditions, and teaches patients how to properly brush and floss at home.

A minimum of two years of college in an accredited dental hygiene program is required to become a registered dental hygienist. Before getting licensed, however, the hygienist must pass state and national board exams.



Dental assistant

Dental Assistant

The dental assistant helps the dentist work quickly and efficiently. He or she sterilizes instruments, mixes filling materials, rinses debris out of the patient's mouth, and hands tools to the dentist. The training requirements and responsibilities of this position vary by state. A certified dental assistant (CDA) has completed a one-year ADA-approved training program.

Dental Technician

The dental technician is the person on the dentist's team who creates artificial teeth and sets of dentures. These detail-oriented professionals use their artistic talents in working with metal, dental porcelain and acrylics, and even computer-aided design to make dental implants that perfectly fit each patient. They work directly with dentists and orthodontists and have little patient contact.

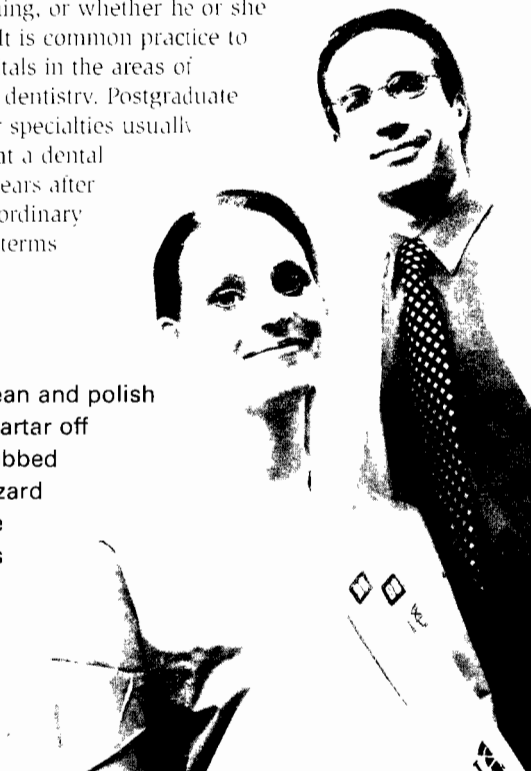
Education and Cost of Training

The basic training for dentists is four years of dental school after graduation from college. Upon successful completion of dental school requirements, the graduate is awarded a doctor of dental surgery (D.D.S.) or a doctor of dental medicine (D.M.D.) degree. To practice, he or she must pass both a written national board and a state or regional examination. After passing the boards, the dental school graduate may apply to the state board of dentistry for a license to practice general dentistry. Some people go right into practice; others may enter a one- or two-year residency program in general dentistry; and still others may choose to train for one of the dental specialties.

A minimum of two years of postgraduate training in a program sponsored by a dental school or hospital is required to become a dental specialist. After successfully completing the requirements, the dentist is "board eligible." If he or she passes the board for that specialty, then he or she becomes "board certified." Certificates, not degrees, are awarded for advanced study.

The sponsoring institution may decide whether the dentist must pay for his or her advanced training, or whether he or she should receive a stipend (allowance). It is common practice to offer paid residency programs in hospitals in the areas of pedodontics, oral surgery, and general dentistry. Postgraduate training in dental schools for the other specialties usually require tuition. When you consider that a dental specialist has trained for six or more years after college, you will realize what an extraordinary commitment that person has made in terms of time and money

Slaves in ancient Rome had to clean and polish their masters' teeth. They picked tartar off with sharpened sticks and then rubbed on powders made from burned lizard livers and honey or urine to make them shine. Little did these slaves know that they were blazing a trail for dental hygienists.



Dentistry Resources

Scouting Literature

First Aid, Medicine, and Public Health
merit badge pamphlets

For more information about
or to order Scouting-related
resources, visit the BSA's
online retail catalog at
<http://www.scoutstuff.org>.

Books

- Betancourt, Jeanne. *Smile!
How to Cope with Your Braces*.
Alfred A. Knopf, 1982.
- Ichord, Loretta Frances. *Toe:hworms
and Spider Juice: An Illustrated
History of Dentistry*. The Millbrook
Press, 2000.
- Klatell, Jack, Andrew Kaplan, and
Gray Williams Jr. *The Mount Sinai
Medical Center Family Guide to
Dental Health*. Macmillan Publishing
Company, 1991.
- Lee, McHenry, Joleen Jackson, and
Vicki J. Audette. *I Hate Dentists!
The Feel Good Guide to Going to
the Dentist*. IHD Publishing, 1999.
- Marsoli, Lisa Ann. *Things to Know
About Going to the Dentist*. Silver
Burdett Company, 1984.
- Moss, Stephen J. *Your Child's Teeth.
A Parent's Guide to Making and
Keeping Them Perfect*. Houghton
Mifflin Company, 1977.
- Ring, Malvin. *Dentistry: An Illustrated
History*. Harry N. Abrams Inc., 1985.
- Silverstein, Alvin, and Virginia B.
Silverstein. *So You're Getting Braces:
A Guide to Orthodontics*. J. B.
Lippincott Company, 1978.
- Smith, Rebecca W., and the Columbia
University School of Dental and Oral
Surgery. *The Columbia University
School of Dental and Oral Surgery's
Guide to Family Dental Care*.
W. W. Norton & Company, 1997.
- Taintor, Jerry F., and Mary Jane Taintor.
*The Oral Report: The Consumer's
Common Sense Guide to Better
Dental Care*. Facts On File
Publications, 1988.
- Ward, Brian R. *Dental Care*. Franklin
Watts, 1986.
- Wynbrandt, James. *The Excruciating
History of Dentistry: Toothsome Tales
and Oral Oddities From Babylon to
Braces*. St. Martin's Press, 1998.

Organizations and Web Sites

Academy of General Dentistry

211 E. Chicago Ave., Suite 900
Chicago, IL 60611-1999
Toll-free telephone: 888-243-3368
Web site: <http://www.agd.org>

American Academy of Oral and Maxillofacial Pathology

214 N. Hale St.
Wheaton, IL 60187
Toll-free telephone: 888-552-2667
Web site: <http://www.aaomp.org>

American Academy of Oral and Maxillofacial Radiology

P.O. Box 1010
Evans, GA 30809-1010
Telephone: 706-721-2607
Web site: <http://www.aaomr.org>

American Academy of Pediatric Dentistry

211 E. Chicago Ave., Suite 700
Chicago, IL 60611-2663
Telephone: 312-337-2169
Web site: <http://www.aapd.org>

American Academy of Periodontology

737 N. Michigan Ave., Suite 800
Chicago, IL 60611-6660
Telephone: 312-787-5518
Web site: <http://www.perio.org>

American Association of Endodontists

211 E. Chicago Ave., Suite 1100
Chicago, IL 60611-2691
Toll-free telephone: 800-872-3636
Web site: <http://www.aae.org>

American Association of Oral and Maxillofacial Surgeons

9700 W. Bryn Mawr Ave.
Rosemont, IL 60018-5701
Telephone: 347-678-6200
Web site: <http://www.aaoms.org>

American Association of Orthodontists

401 N. Lindbergh Blvd.
St. Louis, MO 63141-7816
Telephone: 314-993-1700
Web site: <http://www.braces.org>

American Association of Public Health Dentistry

P.O. Box 7536
Springfield, IL 62791-7536
Telephone: 217-391-0218
Web site: <http://www.aaphd.org>

American College of Prosthodontists

211 E. Chicago Ave., Suite 1000
Chicago, IL 60611
Telephone: 312-573-1260
Web site: <http://www.prosthodontics.org>

American Dental Assistants Association

35 E. Wacker Drive, Suite 1730
Chicago, IL 60601-2211
Telephone: 312-541-1550
Web site: <http://www.dentalassistant.org>

American Dental Association

211 E. Chicago Ave.
Chicago, IL 60611-2678
Telephone: 312-440-2500
Web site: <http://www.ada.org>

**American Dental
Education Association**

1400 K St. NW, Suite 1100
Washington, DC 20005
Telephone: 202-289-7201
Web site: <http://www.adea.org>

**American Dental
Hygienists' Association**

444 N. Michigan Ave., Suite 3400
Chicago, IL 60611
Telephone: 312-440-8900
Web site: <http://www.adha.org>

Academy of Comprehensive Esthetics

Web site: <http://www.ACEsthetics.com>

Dentalsite

Web site: <http://www.dentalsite.com>

HealthWeb

Web site: <http://www.healthweb.org>

Acknowledgments

The Boy Scouts of America is grateful to Kent Smith, D.D.S., for his expertise and assistance with this merit badge pamphlet. Thanks to Dr. Smith and Dr. Jeff Roy for the use of their facilities at 21st Century Dental in Irving, Texas. We thank Dr. Smith, Dr. Roy, and their staff members, who went beyond the call of duty to help make possible the photography in this edition of the *Dentistry* merit badge pamphlet.

Thanks to Troop 175, Irving, Texas, and Troop 788, Dallas, Texas, for their assistance with photography.

We appreciate the Quicklist Consulting Committee of the Association for Library Service to Children, a division of the American Library Association, for its assistance with updating the resources section of this merit badge pamphlet.

Photo and Illustration Credits

21st Century Dental, Irving, Texas, courtesy—pages 15 (*bottom, both*), 17 (*bottom*), 23 (*bottom*), 41 (*top and bottom*), 45–46, 49–52, 57 (*both*), and 58 (*top, both*)

21st Century Dental, Irving, Texas, and Michael Roytek (*photo illustration*)—page 40 (*left and right*)

Library of Congress, Prints and Photographs Division, courtesy—pages 4, 9 (*bottom*), and 53 (*top*)

©Photos.com—pages 2 (*top*), 3, 10 (*background*), 12, 13 (*both*), 14 (*bottom*), 15 (*top*), 17 (*top*), 18, 19 (*bottom*), 22 (*photo*), 23 (*top*), 24–25, 27 (*bottom right*), 28, 30 (*both*), 32 (*all*), 34–35, 39 (*right*), 42 (*top*), 47, 53 (*bottom*), 55, 58 (*bottom*), 59, and 61

Wikipedia.org, courtesy—pages 6, 8, and 9 (*top*)

All other photos and illustrations not mentioned above are the property of or are protected by the Boy Scouts of America.

Dan Bryant—pages 20, 38 (*center*), 41 (*center, both*), 42 (*bottom*), and 43 (*all*)

John McDearmon—pages 11, 14 (*illustrations*), 16 (*illustration*), 19 (*illustration*), 21, 22 (*illustration*), and 44